

## Introduction

Eosinophilic esophagitis (EoE) is a chronic disease characterized by eosinophilic inflammation of the esophagus. This inflammation can lead to fibrotic remodeling of the esophagus. Fibrostenotic features such as rings and strictures can be visualized during endoscopy and serve as indicators of remodeling. However, children with EoE often lack these features. Identifying lamina propria (LP) fibrosis in esophageal biopsies has become a method of identifying early remodeling. However, biopsies obtained by endoscopy often lack adequate LP for proper evaluation of fibrosis. We have previously shown that biopsies obtained by standard capacity Radial Jaw™ 4 forceps often lack adequate LP in esophageal eosinophilia cases. The purpose of this study was to: 1) evaluate the LP yield in pediatric EoE cases using a standardized sampling technique consisting of perpendicular placement of the forcep, suction, and single bite; 2) evaluate the relationships between esophageal level (i.e., proximal, mid, or distal), LP yield, intraepithelial eosinophilia, and fibrosis.

Table 1. Patient Characteristics

Clinical Characteristics	All Endoscopic Cases (N=30)
Age, mean (range in years)	8.7 (2-16)
Male, n (%)	17 (57)
White, n (%)	21 (70)
On Therapy <sup>a</sup> , n (%)	23 (77)
Cases with Other Diagnosis of Eosinophilic GI Diseases <sup>b</sup> , n (%)	7 (23.3)
<b>Symptoms, n (%)</b>	
Dysphagia	17 (57)
Heart Burn or Chest Pain	6 (20)
Abdominal Pain	14 (47)
Vomiting	9 (30)
Feeding Difficulty	11 (37)
Diarrhea	2 (7)
Food Impaction	1 (3)
Poor Weight Gain, Weight Loss, or Failure to Thrive	8 (27)
<b>Endoscopy Features, n (%)</b>	
Edema	22 (73)
Rings	3 (10)
Exudates	8 (27)
Furrows	20 (67)
Strictures	0 (0)

<sup>a</sup>Therapy includes proton-pump inhibitors, topical steroids, systemic steroids, and dietary therapy.  
<sup>b</sup>Other eosinophilic GI diseases include eosinophilic gastritis, eosinophilic gastroenteritis, and eosinophilic colitis.

Table 2. LP Yield in EoE Cases

	Active EoE Cases N=19	Inactive EoE Cases N=11	P Value
Cases with Inadequate LP, n (%)	3 (16)	6 (55)	0.02
Cases with Normal LP, n (%)	3 (16)	2 (18)	
Cases with Fibrosis Detected, n (%)	13 (68)	3 (27)	

Table 3. LP Yield in Biopsy Tissue Fragments

	Biopsy Tissue Fragments from Active EoE Cases N=159	Biopsy Tissue Fragments from Inactive EoE Cases N=96	P Value
Biopsy Tissue Fragments with Inadequate LP, n (%)	92 (58)	77 (80)	<0.0001
Biopsy Tissue Fragments with Normal LP, n (%)	25 (16)	12 (12.5)	
Biopsy Tissue Fragments with Fibrosis Detected, n (%)	42 (26)	7 (7.3)	

## Methods

We reviewed consecutive EoE endoscopic cases performed by a single endoscopist in 1/1/2018 to 12/31/2018, who placed the opened biopsy forceps perpendicularly to the esophageal mucosa, applied suction to fully collapse the esophageal wall around the forceps, and took a single bite when obtaining all esophageal biopsy samples. For each case, the same number of biopsies were taken from each esophageal level. Archived H&E slides had consensus evaluation by two study pathologists to determine the peak intraepithelial eosinophil (eos) count per high power field (HPF), LP adequacy for fibrosis evaluation, and LP fibrosis of each biopsy tissue fragment. Biopsy tissue fragments containing LP without crush artifact (i.e., elongated and distorted fibroblast nuclei) were considered adequate for fibrosis evaluation. Cases with significant esophageal eosinophilia ( $\geq 15$  eos/HPF) were categorized as active EoE cases. Cases with minimal or no esophageal eosinophilia ( $< 15$  eos/HPF) were categorized as inactive EoE cases.

## Results

The endoscopist took a total of 237 biopsies from the 30 EoE cases (Table 1); due to tissue fragmentation during histology processing, 255 biopsy tissue fragments were analyzed. Overall, 21 (70%) cases had at least 1 fragment with adequate LP for fibrosis evaluation; however, only 86 (34%) fragments had adequate LP. Active EoE cases were more likely to have fibrosis detected, while inactive EoE cases were more likely to be inadequate (Table 2). Three inactive EoE cases still had evidence of fibrosis. Fragments from active EoE cases demonstrated significantly higher rates of adequate LP than inactive cases (Table 3). There were no significant differences in adequate LP yield per fragment among the 3 levels of the esophagus (Fig 1A). However, fragments from the distal and middle esophagus had significantly higher eosinophilia than the proximal esophagus (Fig 1B). Fibrosis was patchy and most often detected in the mid-distal esophagus in the 13 EoE cases with fibrosis (Fig 1C). Fragments with adequate LP had significantly higher eosinophilia than those with inadequate LP ( $25 \pm 30$  vs.  $14 \pm 23$  eos/HPF,  $p < 0.0001$ ). Fragments with LP fibrosis demonstrated significantly higher eosinophilia than those with normal LP or inadequate LP (Fig 2).

Figure 1

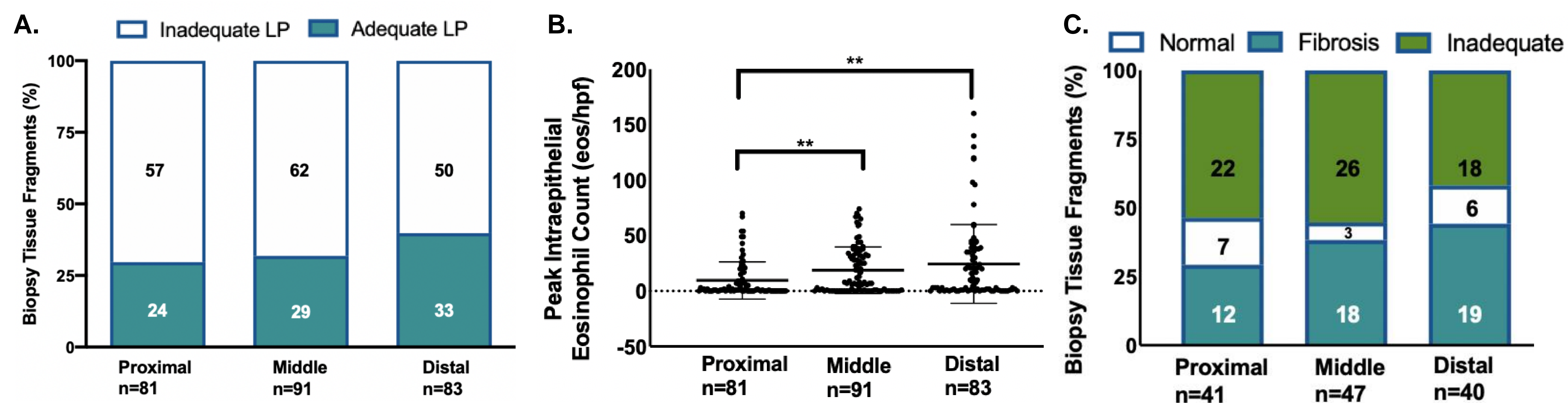
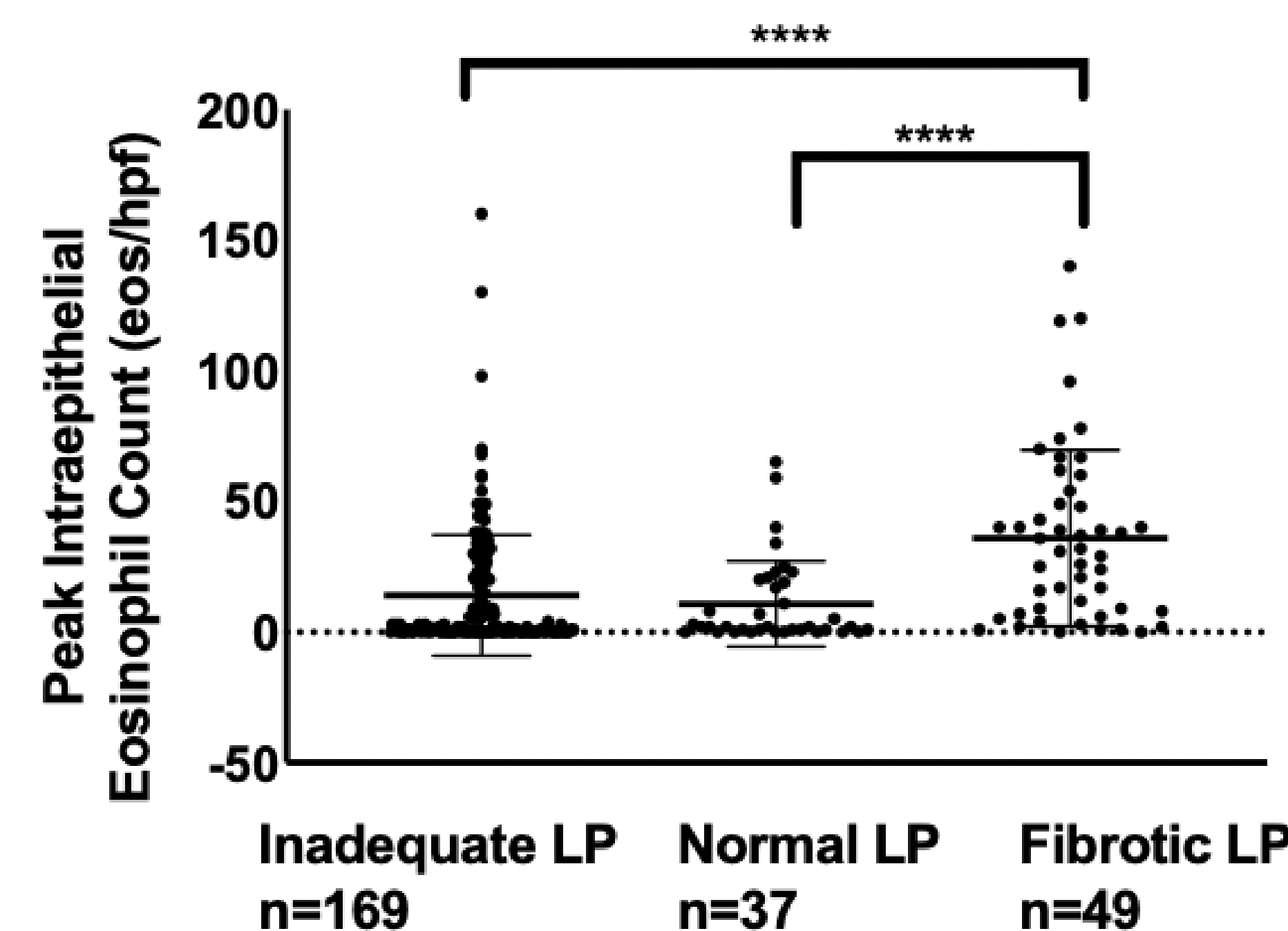


Figure 2



## Conclusions

LP yield per biopsy tissue fragment using a perpendicular placement of forceps is low. While LP yield is not influenced by esophageal level, both adequate LP and fibrosis are associated with higher esophageal eosinophilia, and esophageal eosinophilia is higher in the middle and distal esophagus. Thus, sampling from the middle-distal esophagus might optimize detection of fibrosis in pediatric EoE.