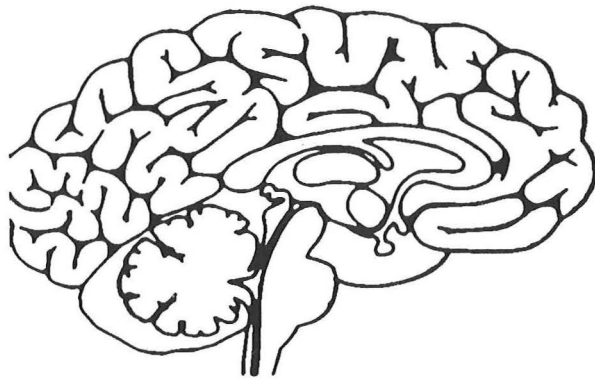


# **Focal Neurological Disease in AIDS: New Insights into Diagnosis**

**Daniel Skiest, M.D.**



**Internal Medicine Grand Rounds  
The University of Texas Southwestern Medical Center  
August 31, 2000**

"This is to acknowledge that Daniel Skiest, M.D. has disclosed no financial interests or other relationships with commercial concerns related directly or indirectly to this program. Dr. Skiest will be discussing "off-label" uses in his presentation."

**Biographical Information**

Name: Daniel J. Skest, M.D.

Rank: Associate Professor

Division: Infectious Diseases

Interests: My major interests are clinical aspects of HIV particularly CMV and other opportunistic infections and neurological complications of HIV.

In the past few years we have witnessed significant advances in understanding the pathogenesis of HIV. This progress has led to successful therapy for many HIV-infected patients. In the United States the morbidity and mortality due to HIV has declined substantially. The number of AIDS cases declined from 68,505 in 1995 to 46,400 in 1999, while the death rate decreased from 49,456 to 10,122 over the same period [1]. Much of the recent progress is attributable to highly active antiretroviral therapy (HAART), which consists of several drugs used in combination. Due in part to the recent therapeutic advances the prevalence of AIDS has actually increased in the past few years, since the number of people diagnosed with HIV and AIDS annually exceeds the number of deaths. As patients live longer with this disease it is likely that they will continue to be at risk for experiencing complications.

The nervous system is an important target of HIV. The prevalence of neurologic disease in symptomatic HIV-infected patients has been estimated to be 39-70% [2-5]. Approximately 7-20% of patients with AIDS will initially present with a neurologic complication [3, 4]. In post-mortem studies from the pre-HAART era the incidence of neurological abnormalities ranged from 62-90% [2, 5-7]. A recent study demonstrated that central nervous system (CNS) disease remains an important complication in patients with HIV. In a review of 390 autopsies of AIDS patients, pathology was found in 63% of brains, which made the brain the second most commonly involved organ after the lung [6].

#### Direct effects HIV on the Central Nervous System (CNS)

HIV is a neurotropic virus which affects the CNS at the earliest stages of infection. Patients may present clinically with aseptic meningitis during the acute retroviral syndrome, a flu-like illness which is the earliest clinical manifestation of HIV. This initial infection with HIV which is characterized by widespread viremia also leads to seeding of the central nervous system. It appears that the virus is able to cross the blood brain barrier by infecting monocytes, which readily traffic in the CNS.

NEUROLOGICAL COMPLICATIONS OF HIV	
Primary Processes	Secondary Processes
HIV dementia	Toxoplasmosis
Vacuolar Myelopathy	PML
Cerebrovascular disease	Primary CNS lymphoma
Inflammatory demyelinating polyneuropathy	<i>Cryptococcus neoformans</i>
Aseptic meningitis	Cytomegalovirus Encephalitis
Distal symmetrical polyneuropathy	Tuberculous meningitis
Mononeuritis multiplex	Neurosyphilis
Myopathy	<i>Nocardia</i>
	<i>Aspergillus</i>
	CMV Polyradiculopathy

Any part of the nervous system may be affected by HIV including the brain, spinal cord and peripheral nervous system (Table). Both primary and secondary complications occur. Primary complications are those caused by HIV itself, while secondary complications are those opportunistic processes (infections and malignancies) which occur as a consequence of the immunosuppression caused by HIV. Primary processes include HIV dementia, myelopathy,

distal sensory polyneuropathy and myopathy. Secondary processes include infections such as toxoplasmosis, cryptococcus, JC virus and cytomegalovirus as well as malignancies (primary CNS lymphoma). In terms of frequency the most common process involving the brain at post-mortem is HIV, followed by cytomegalovirus (CMV), Non-Hodgkin's Lymphoma (NHL) fungi, progressive multifocal leukoencephalopathy (PML) and toxoplasmosis [6]. This review will focus on secondary CNS complications.

It was recognized in the early part of the HIV epidemic that diagnosing focal CNS manifestations was difficult with non-invasive methods, since different processes may appear similar on neuroimaging studies and most agents cannot be cultured with conventional techniques. Recently, several new techniques have been developed which have led to improved diagnostic accuracy of the focal CNS manifestations of AIDS. These tests include the polymerase chain reaction (PCR) and functional neuroimaging studies.

In the past several years use of DNA amplification techniques, e.g. the polymerase chain reaction (PCR), has revolutionized clinical microbiology and clinical infectious diseases. Organisms which previously were either not able to be cultivated or were able to be cultured only with very sophisticated and laborious techniques can now be identified promptly with this new technology. Through PCR techniques tiny quantities of virus (or other organisms) can be amplified greatly, thus allowing detection of the organism. PCR has been especially useful in the diagnosis of CNS focal disease in HIV-infected individuals.

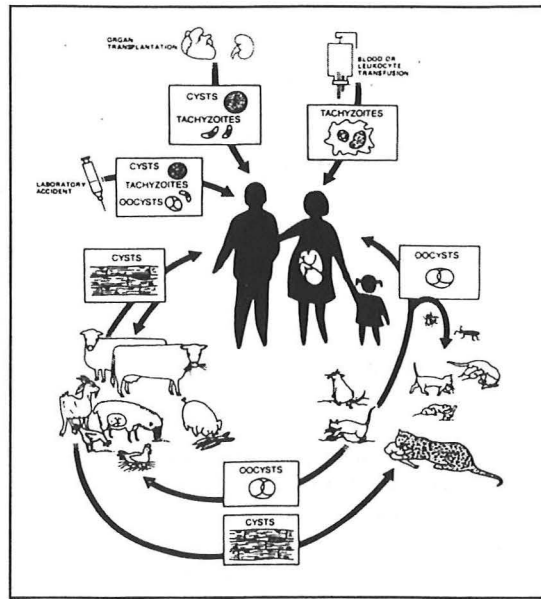
## **SECONDARY CNS PROCESSES**

### **Focal CNS Lesions**

Toxoplasmosis- *Toxoplasma gondii*, an intracellular parasite, has traditionally been the most common etiology of focal CNS disease in patients with AIDS [4, 8]. The parasite has been found in the brain of 2.5-13% of patients at autopsy [5-7]. However, due to the widespread use of prophylaxis for toxoplasmosis combined with the lack of effective prophylactic therapy for other causes of focal brain lesions, e.g. lymphoma and PML, the relative incidence of toxoplasmosis may be declining. In one study, the incidence of *T. gondii* as a cause of focal brain lesions decreased from 72% in 1991 to 19% in 1996 [9].

Life cycle- The life cycle of toxoplasmosis is complex. The parasite can undergo both sexual and asexual reproduction in the cat, the definitive host. Man is an intermediate host. Cats become infected after ingestion of either oocysts from contaminated food or water, or ingestion of tissue cysts from the tissues of intermediate hosts. In the cat intestine the infective stages (bradyzoites from tissue cysts and sporozoites from oocysts) are liberated and spread to other organs. Oocysts may also be produced in the cat intestine where they are shed in feces, thereby completing the life cycle. Humans and other intermediate hosts are infected by ingesting oocysts in infected soil or in cat litter. The asexual stage takes place in both cats and intermediate hosts and occurs when tachyzoites (formed from sporozoites or bradyzoites) invade the bloodstream and disseminate to other organs including muscle, lymphatics, liver, spleen and the brain. Tissue cysts are formed in host tissues by tachyzoites. The tissue cyst forms of the parasite persist for life in the host. Animals including humans may also become infected by ingesting meat (pork and lamb) containing tissue cysts, which release tachyzoites in the intestine [10, 11].





In immunosuppressed patients including those with AIDS, toxoplasmic encephalitis is primarily due to reactivation of latent infection. Following the initial infection, the immune system is activated and controls the acute infection. Unless, host immunosuppression occurs subsequently, the patient remains without any signs or symptoms of disease. The risk of toxoplasmosis correlates with CD4 cell count. Most patients (over 80%) who develop disease have a CD4 cell count less than 100 cells/ $\mu$ L [11, 12]. The median CD4 cell count has ranged from 34-50 cells/ $\mu$ L in most studies [12-14].

The incidence of toxoplasmosis in AIDS patients varies by country due

#### ***Toxoplasma gondii* life cycle**

to the varied seroprevalence of toxoplasmosis in different regions of the world and among different socioeconomic groups. In the United States the seroprevalence varies from 3-30%, while in France 73-90% of the population is infected [13]. Approximately 10-40% of HIV-infected adults in the U.S. had antibodies to *T. gondii* in one study [11]. Studies from the pre-HAART era, estimated that approximately 5-47% of latently infected individuals would develop CNS toxoplasmosis [10, 11, 13]. Current estimates are lower due to the widespread use of prophylaxis and the effects of HAART.

**Pathology-** Lesions of toxoplasmosis begin as a focus of encephalitis which progress to parenchymal abscesses with necrosis and surrounding inflammation. Tachyzoites are usually located at the periphery of the lesions. Lesions may be unifocal or multifocal and can vary in size from microscopic to quite large. While any part of the brain can be involved, lesions are most commonly located in the parietal or frontal lobes, at the corticomedullary junction, basal ganglia, thalamus and pituitary gland [13, 15, 16]. Both the gray and white matter can be involved. Rarely, spinal cord disease occurs [17].

**Clinical Manifestations-** Typically patients have a subacute presentation over several weeks, although an acute presentation can sometimes occur. Most of the clinical manifestations arise from focal parenchymal involvement of the brain. The most common presenting signs and symptoms are headache (49-55%), fever (41-47%), psychomotor or behavioral changes (37-38%), confusion (15-52%), lethargy (12-43%), hemiparesis (39-49%), seizures (24-29%), ataxia (30%) and cranial nerve palsies (17-28%) [12, 13]. Meningeal signs are uncommon. Up to 10% of patients may present with a diffuse encephalitis without any visible focal lesions [16]. Although the disease can affect other organ systems including the retina, heart, lung and gastrointestinal tract, symptoms of disease outside the CNS are uncommon.

Neuroradiology- The typical CT and MRI findings in toxoplasmosis are two or more ring enhancing lesions in the cerebrum and/or the basal ganglia with surrounding edema. However, radiographic findings can be variable; studies have revealed that up to 27-43% of patients have a single lesion on imaging studies [12-14, 18] . As noted above, lesions are often located at the corticomedullary junction and the basal ganglia. Small areas of hemorrhage can be seen in some lesions. On T1 weighted MRI the lesions appear as focal areas of low signal intensity, which enhance (usually ring enhancing) with gadolinium. T2 weighted MRI lesions are relatively high signal. Occasional lesions will not enhance with contrast [13] . Magnetic resonance imaging (MRI) is more sensitive than CT and will often detect more lesions. Treated lesions may have calcifications.

Standard cerebrospinal fluid tests are rarely diagnostic, since the findings in patients with toxoplasmosis are non-specific. CSF may reveal elevated protein, mild lymphocytic pleocytosis and occasionally hypoglycorachia, but is often normal [13] .

Reflecting the fact that in AIDS patients toxoplasmosis is due to reactivation, most patients with CNS toxoplasmosis have serological evidence of infection. A number of methods have been used to show evidence of infection with *T. gondii*. The gold standard is the Sabin-Feldman dye test, but the test is limited by the fact that it is cumbersome and not readily available. Indirect fluorescent antibody (IFA) and ELISA are the tests most commonly used by clinical laboratories.

Since infection with *T. gondii* is widespread, a positive serology is not very helpful diagnostically. However, most studies have demonstrated a high negative predictive value of serum IgG antibodies, since less than 3-6% of patients with toxoplasmosis will have negative Toxoplasma serology [19-22] . A few studies have suggested higher rates of seronegativity in AIDS patients with confirmed toxoplasmosis (up to 17%) [12, 15, 23] . Reasons for the discrepancies among the studies may include the different methods used to measure antibodies, and the fact that some studies reported clinical diagnoses of toxoplasmosis rather than a pathologically confirmed diagnosis. In addition, occasionally in AIDS patients with CNS toxoplasmosis, serum titers may wane with advanced immunosuppression. Although CNS toxoplasmosis occurs due to reactivation, a significant rise in antibody titers is uncommon. The value of intrathecal antibodies against *T. gondii* is debatable. One study suggested a high specificity but a sensitivity of only 69% [24] . CSF antibodies may be negative in patients with positive serum serology and proven toxoplasmosis [25] .

PCR for *T. gondii* DNA of spinal fluid has been disappointing to date. In general the test has had a reasonable specificity of 96-100% but a low sensitivity of about 50% [26-29] . Similarly, PCR for *T. gondii* DNA in blood has not been useful [30] . Thus, PCR for *T. gondii* has not been adopted for use in most clinical situations.

Diagnosis- While certain clinical and radiographic findings (e.g. positive toxoplasma serology, lack of toxoplasma prophylaxis, multiple lesions versus a single lesion, etc) may favor a diagnosis of toxoplasmosis over CNS lymphoma and occasionally other processes, the presentation of these entities overlaps significantly. Thus, more definitive criteria are required to establish a diagnosis. The definitive diagnosis of toxoplasmosis requires a brain biopsy with the demonstration of tachyzoites. However, in practice most patients with AIDS and multiple ring enhancing lesions who have a positive serum Toxoplasma serology are treated empirically. Most

patients will respond promptly to appropriate therapy. Of patients who eventually improve, 86% will show clinical improvement by day 7 and 95% of patients on appropriate therapy will show radiographic improvement by day 14 [12, 14] . If no improvement is seen by two weeks then alternative diagnoses should be considered as discussed below.

**Treatment-** Treatment of toxoplasmosis in AIDS with standard medications is successful in over 70-85% of patients [12-14, 31, 32] . The treatment of choice for toxoplasmic encephalitis is the combination of pyrimethamine plus sulfadiazine, which act by inhibiting two enzymes involved in folate metabolism, dihydrofolate reductase and tetrahydrofolate synthetase, respectively [14, 23, 33] . Folinic acid is added to prevent bone marrow toxicity due to pyrimethamine, since it can be used by eukaryotic cells but not by *T. gondii*. In the pre-HAART era, median survival with treatment was approximately 10 months [13] . Unfortunately, HIV-infected patients have a high incidence of sulfa allergy and may not be able to tolerate sulfadiazine. Several randomized controlled trials have demonstrated that pyrimethamine plus clindamycin is a reasonable alternate regimen which is better tolerated; however, it may be somewhat less efficacious [13, 31, 32] . Alternative medications for which there is either anecdotal evidence of efficacy or theoretical potential for patients intolerant of one of the above regimens include azithromycin, clarithromycin, atovaquone, trimetrexate or dapsone [34-38] . Many authorities would use one of these medications in combination with pyrimethamine.

Induction therapy is generally given for six weeks. Maintenance therapy is necessary with lower doses of same regimen used in induction therapy. In patients who experience excellent virological and immunological response to HAART there is accumulating evidence that maintenance therapy can eventually be discontinued with little or no risk of relapse [39] .

### **Primary CNS lymphoma**

Non-Hodgkins Lymphoma (NHL) is the second most common AIDS related malignancy [6] . The incidence of NHL in AIDS is increased approximately 100 fold compared to the general population [40] . Primary CNS lymphoma accounts for about 10-20% of all HIV related NHL and is up to 3600 fold more common in patients with AIDS than in the general population [41, 42] . In studies from the early years of the AIDS epidemic approximately 4-7% of patients with neurological complaints were diagnosed with primary CNS lymphoma [4, 43] while the rate of primary CNS lymphoma at post-mortem was reported to be 0.6-5.0% [5, 7, 41] .

In most series, primary CNS lymphoma is the second most common cause of focal brain disease in patients with AIDS. One study showed a trend towards increasing incidence of primary CNS lymphoma in AIDS patients with focal brain lesions from 1991 to 1996 [9] . Some studies have suggested that NHL has not decreased with HAART to the same extent as other AIDS related conditions [44] . The reasons for this are not clear.

**Pathology-** Lesions usually occur supratentorially and are often multicentric but solitary lesions occur in one third to one half of cases [45-48] . Almost all are of high grade, B-cell phenotype and are very aggressive. The most common histology is either large-cell, immunoblastic or small, non-cleaved cell [47, 48] . Lesions are characterized by perivascular involvement, high mitotic rates and variable amounts of necrosis. Disease outside the CNS is distinctly uncommon.

Pathophysiology- Evidence of Epstein-Barr virus (EBV) can be found in nearly 100% of AIDS related primary CNS lymphomas, while about 50% of lymphomas outside the CNS are associated with EBV [46, 49] . The EBV genome is incorporated into the genome of the lymphoma cells. However, the precise role of EBV in the pathogenesis is controversial. It is known that EBV can transform B cells in vitro and it is postulated that it contributes to neoplastic transformation in the setting of the uncontrolled B cell stimulation and proliferation which occurs due to the severe immune dysregulation of late stage HIV [49, 50] . The depletion of EBV specific CD8+ T-cells, which occurs in late stage AIDS likely contributes by allowing increases in EBV replication. In addition, the central nervous system may be an immunologically privileged site which is not subject to the same immune surveillance as the rest of the body. Mutations in tumor suppressor genes such as *p53* and others may also play a role [45, 49] .

Diagnosis-This is a late manifestation of HIV and usually occurs at very low CD4 counts (< 50) [47, 51] . Compared to AIDS patients with systemic NHL, patients with primary CNS lymphoma have significantly lower CD4 cell counts. Patients frequently have other manifestations of AIDS at the time of diagnosis and often have a poor functional status [52, 53] . In one study of 55 patients with primary CNS lymphoma three-fourths of patients had prior opportunistic infections [48] .

The most common signs and symptoms of primary CNS include altered mental status (confusion, memory loss, lethargy) in 48-60% of cases, hemiparesis, dysphasia or sensory findings in 31-78%, seizures in 15-41%, cranial nerve findings in 10-18%, and headache 5-45% [46-48, 52, 53] . The majority of patients have B symptoms at the time of presentation, although it is not clear whether these symptoms are related to the lymphoma or concomitant opportunistic infections. The mean duration of symptoms prior to diagnosis has been reported to be between 22 and 54 days [47, 54, 55] , which is shorter than for non-AIDS patients with CNS lymphoma. CNS disease can also occur in patients with systemic NHL. However, the usual CNS presentation is leptomeningeal involvement, rather than parenchymal disease.

Neuroimaging- CT or MRI will show a single or multiple hypodense lesions, which enhance with contrast (usually homogenous enhancement but sometimes ring enhancement), and exhibit mass effect with surrounding edema [9, 47] . Lesions which do not appear on CT may be apparent on the more sensitive MRI. Lesions are located in the cerebrum, basal ganglia, cerebellum, and occasionally brainstem. Involvement of the corpus callosum may also be seen. Location of lesions adjacent to CSF pathways, e.g. periventricular or meningeal as well as subependymal spread of lesions are characteristic findings.

Evaluation of CSF is usually not helpful except to exclude other diagnoses. The CSF findings often include elevated protein and mild pleocytosis with a mononuclear cell predominance, but these findings are not specific [53] . CSF cytology is diagnostic in about 10-30% of NHL in non-AIDS patients, but has lower sensitivity in AIDS patients [47, 53] .

Role of PCR- The fact that primary CNS lymphomas are universally associated with EBV has resulted in a useful diagnostic test. Several studies have shown promise for CSF EBV PCR for diagnosis [56, 57] . Both Cinque et al, and Weber et al, recently reviewed this topic and found that the sensitivity of CSF EBV PCR ranged from 50-100% and the specificity from 94-100%

[27, 58] . However, the majority of studies demonstrated a sensitivity of greater than 80% [57] . In addition, the test appears to have a high positive and negative predictive value. In some patients EBV DNA has been detected in spinal fluid prior to radiographic evidence of lymphoma. Unfortunately, spinal fluid can not be safely obtained in all patients (e.g. those with significant mass effect), which prevents its universal utility. EBV PCR has quickly evolved to the point where it is considered standard of care in patients with focal enhancing CNS lesions.

Recently, a small study suggested a role for following quantitative EBV DNA levels in the spinal fluid. In this study in which nine patients were treated for primary CNS lymphoma with chemotherapy and whole brain radiation, changes in EBV DNA burden correlated with response to therapy. Survival time was doubled in patients with at least a one log reduction in EBV DNA [59] .

Treatment- In the pre-HAART era the median survival for untreated patients with primary CNS lymphoma was 1-2.5 months [42, 47, 54, 55] . Tumor resection has not been shown to improve prognosis. Furthermore, since most often the tumor is multifocal complete surgical resection is usually not possible.

Cranial whole brain radiation (usual dose of 2000-4500 cGy) is effective in 50-75% of patients in shrinking the tumor and in improving symptoms; however, most studies have only documented a median survival benefit of 1-3 months [47, 48, 51, 52, 54, 55, 60, 61] . In most of these studies, patients died from other causes related to their severe immunosuppression [53, 55] . Karnofsky performance status has been shown to correlate with outcome [55] .

Chemotherapy has been disappointing in the past, but now with better treatment for HIV, chemotherapy may be a consideration in the future. A small uncontrolled study suggested a benefit from intravenous methotrexate and corticosteroids [62] . However, this study was confounded by the use of HAART in most of the patients. Combination therapy may also be beneficial. In a recent study in which patients with good prognostic criteria were selected to receive both radiation and chemotherapy the median survival was 13 months, compared to 4 months for those treated with radiation alone [52] .

The role of HAART in the treatment of primary CNS lymphoma is not clear. Other malignancies, most notably Kaposi's sarcoma have been shown to regress on HAART and it is likely that primary CNS lymphoma may also. There is a single case report [63] and one small series which suggested a longer survival among patients who received a protease inhibitor compared to those who did not [62] .

Recently a novel approach was reported in which patients with primary CNS lymphoma were treated with zidovudine, ganciclovir and interleukin 2. The rationale for this regimen is the finding that ZDV has been shown to induce apoptosis in an EBV-positive B-cell lymphoma line; IL-2 has been shown to result in immunorestitution with increased CD4 cell counts and ganciclovir may have activity versus EBV. Four of five patients responded to this regimen [64] . However, these patients also received HAART and it is not clear whether the prolonged survival was due to the treatment regimen or the antiretroviral therapy. It is hoped that earlier diagnosis of primary CNS lymphoma may lead to better outcomes since under current management

algorithms therapy is often delayed for 2 for 4 weeks while patients are treated empirically for toxoplasmosis.

### **Progressive Multifocal Leukoencephalopathy (PML)**

PML is characterized by demyelinating lesions in the central nervous system. Prior to the advent of AIDS, PML was a rare disorder, occurring occasionally in immunosuppressed due to hematologic malignancies or other disorders. Since the early 1980s the majority of cases have occurred in patients with HIV with an overall prevalence in AIDS patients of 0.9-1.8% [4, 65] . PML is found in 2.4-5.3% of AIDS patients at postmortem [5-7, 65, 66] and approximately 18% of HIV-infected patients with central nervous system disease [57] .

Pathogenesis- PML is caused by the JC virus (JCV), a double-stranded DNA containing papovavirus in the genus polyomavirus. This virus infects up to 90% of the population and is usually acquired in childhood or early adulthood. Primary infection is usually asymptomatic. The virus remains latent in lymphocytes in lymphoid tissue and probably the kidney. 5-10% of the population excretes JCV in the urine [66] and virus can be detected in 2.3% of HIV-negative blood donors without evidence of disease [67] . The virus can be activated during periods of immune suppression and enter the bloodstream. The inflammation resulting from HIV infection of the CNS may allow JCV entry into the CNS [66] . Circulating lymphocytes may be able to cross the blood-brain barrier and pass infection to astrocytes at the border of blood vessels [68] .

PML is a late manifestation of HIV which presents in patients with low CD4 cells counts [69-72] . The median CD4 cell count has ranged from 35-104 cells/ $\mu$ L in published studies [71-78] . However a subset of patients (7-25%) have had CD4 cell counts > 200 cells/ $\mu$ L [65, 69, 70, 72, 77] . In addition to the effects of the immunosuppression of AIDS, there may be additional factors which result in a relatively high incidence of PML in AIDS patients compared to other immunosuppressed populations. Studies suggest an interaction occurs between HIV and JCV. The JCV T protein (responsible for initiation of viral DNA replication and transcription of the viral capsid proteins) can transactivate the HIV long terminal repeat (LTR). In addition, HIV *tat* can increase transcription from the JCV regulatory region.

Pathology- The characteristic findings are multifocal demyelination, hyperchromatic enlarged nuclei of oligodendrocytes, and enlarged bizarre astrocytes with lobulated hyperchromatic nuclei. Virions can be seen as inclusions in oligodendroglial cells, which are the primary site of infection [66, 68, 79] . Immunohistochemistry, in situ hybridization, or electron microscopy can be used to demonstrate the virions. Demyelinating lesions can occur in any part of the white matter, but occur most commonly in the frontal, parietal and occipital lobes. The posterior fossa may be involved as well.

Signs and symptoms are dependent on the parts of the brain that are involved and include cognitive deficits, speech and visual disturbances, difficulty with gait, hemiparesis, and incoordination of limbs [66] . Visual disturbances which occur in up to 30-50% of patients with PML include either homonymous hemianopsia or quadrantanopsia or cortical blindness. Speech deficits are also common. Seizures occur in approximately 10% of patients [66] .



Neuroradiology- CT reveals hypodense lesions of the white matter without mass effect or enhancement. MRI, which is more sensitive, reveals areas of hypointensity on T1 and increased intensity on T2-weighted images [72, 80] . Mass effect is rarely seen. Enhancement with contrast is uncommon and if present is faint and peripheral [72] . Involvement of the gray matter may occur but only in conjunction with white matter disease [80] . Lesions are usually multiple and bilateral but patients may present with a single focus. Infratentorial disease is not uncommon. The lesions may have a scalloped appearance on MRI due to involvement of subcortical white matter.

Routine CSF studies in PML are generally not diagnostic. CSF may reveal a mildly elevated protein, and myelin basic protein, with a mild mononuclear pleocytosis (less than 20 cells/ $\mu$ L). In a large study of 154 patients with PML, the median CSF cell count was 2, median CSF protein and glucose were 58 ng/dl and 52 mg/dl, respectively [72] .

Role of PCR- JC virus has not been cultured from spinal fluid. However, JCV DNA can be detected by PCR and according to several recent studies appears to have a high degree of sensitivity and specificity. The sensitivity which has ranged from 42-100% in most studies, averages 80% [27, 58] . Lower sensitivity may be noted earlier in the disease course presumably due to lower amounts of virus [81, 82] . Methods to improve sensitivity include using nested PCR and repeating the test on subsequent CSF samples [81] . Specificity is very high (greater than 95%) in most studies [27, 58] . Due to the relatively high positive predictive value of the test, a positive PCR in a patient with a compatible radiological picture can be assumed to have PML. Conversely, a negative test does not completely rule out PML.

More recently several groups have measured JCV by quantitative PCR. Higher levels of JC virus in CSF appear to correlate inversely with survival [78, 83, 84] . Yiannoutsos et al. found that JCV DNA levels above 50 to 100 copies/ $\mu$ L were associated with decreased survival [84] . In addition, clearance of JCV DNA from the CSF has been noted with a beneficial response of PML to HAART therapy [85, 86] .

Diagnosis- The differential diagnosis of PML includes HIV dementia and CMV encephalitis. The former usually is not associated with focal neurological disease, occurs more insidiously and is associated with more cognitive deficits, while the latter is usually located in the periventricular white matter and centrum semiovale. Definitive diagnosis requires brain biopsy; however, as noted above JCV PCR is an important adjunct to diagnosis. In the patient with characteristic signs and symptoms, multiple, non-enhancing white matter lesions, cognitive deficits along with focal findings, and a positive JCV PCR of the CSF the diagnosis is usually PML. In such patients brain biopsy can usually be deferred.

Prognosis- Traditionally the prognosis of PML has been poor, with a median survival of 1-6 months after diagnosis [65, 69, 72, 76, 78] . However a significant minority will have a more benign course with remission and even spontaneous recovery. In a large study by Berger et al. from the pre-HAART era, 6 of 72 (8%) patients with pathologically confirmed PML survived longer than 12 months [72] . Several factors have been associated with a longer survival and are listed in the table.

---

### Factors Associated with Prolonged Survival in PML

---

Receipt of HAART

High CD4 cell count at time of diagnosis

Increase of CD4 cell count by > 100 cells/ $\mu$ L

Low HIV viral load

PML as initial AIDS diagnosis

Low JC virus levels in CSF

---

References [65, 69, 70, 74, 83, 84, 87]

**Treatment-** There is no proven effective treatment for PML. Initially there were anecdotal reports which suggested a possible benefit of the nucleoside analogue, cytosine arabinoside (ARA-C, cytarabine). However subsequent reports have failed to confirm the efficacy of ARA-C

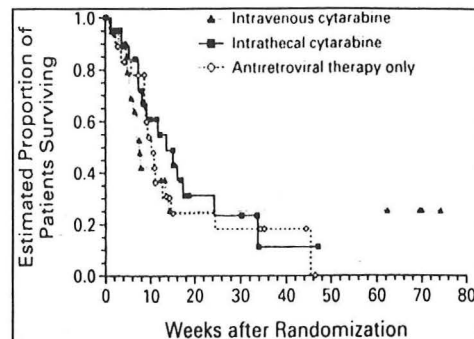


Figure 1. Kaplan-Meier Curves for Survival in the Three Treatment Groups.

[69, 71, 75]. The AIDS Clinical Trials Group conducted the only prospective, randomized controlled trial of ARA-C [75]. This study compared antiretroviral therapy alone to intravenous ARA-C plus antiretroviral therapy, to intrathecal ARA-C plus antiretroviral therapy. Each treatment was given for 24 weeks. In most patients antiretroviral therapy consisted of dual nucleoside analogue therapy. This study was terminated prematurely, because no survival benefit was seen in either of the ARA-C arms. It was concluded that a survival benefit would be unlikely even if the study was completed and that ARA-C would expose patients to added toxicity without a definite benefit.

Hall et al. NEJM, 1998

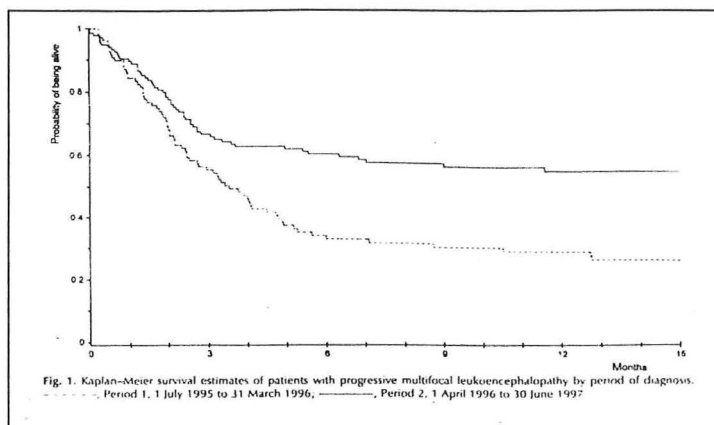
Cidofovir, a nucleotide analogue with broad antiviral activity has been shown to have in vitro activity against the JC virus. Several anecdotal reports have suggested a benefit of cidofovir in patients with PML [83, 88-91]. However, these reports lacked control groups and were usually confounded by concomitant HAART therapy. Recently, a larger study, failed to demonstrate a benefit of cidofovir despite clearance of JC virus from the CSF [92].

Several reports have documented an improved survival in PML patients who receive HAART [65, 70, 73, 74, 77, 78, 85, 93-100]. Clifford et al. compared survival in 25 patients with PML who received HAART to a historical cohort of PML patients enrolled in a clinical study. Median survival in patients receiving HAART was 46 weeks compared to 11 weeks for patients who did not receive HAART [74]. Patients with lower HIV viral loads had a significantly longer survival. Similarly, Dworkin et al found that 68% of patients receiving HAART containing a protease inhibitor survived 6 months compared to 10% of patients not receiving antiretroviral therapy [65]. Tassie et al retrospectively compared survival in 109 PML patients who did not receive a protease inhibitor to 131 who did. They found the six month survival of patients who received protease inhibitors to be almost twice that of those who did not [100]. It appears that the mechanism of HAART in PML is immunorestitution, as evidenced by the correlation with



increased CD4 cell counts and survival as well as the fact that patients on HAART are able to clear JC virus from the CSF [70, 73] .

Thus, HAART has become the standard of care for AIDS patients with PML. However, PML may develop in patients on HAART and patients with PML may not improve neurologically despite a beneficial virologic and immunologic response to HAART [74, 101, 102] .



immune reconstitution syndrome, which is characterized by an enhanced inflammatory response to an infectious agent in patients who respond well to HAART, has recently been described in PML and is characterized by enhancing lesions on neuroimaging studies [103] .

#### Tassie et al AIDS 1999

Other potential treatments for PML are listed below. Clinical data is lacking for those therapies not discussed above.

Treatments for PML	Mechanism	Efficacy
Cytosine arabinoside	nucleoside analogue	no
AZT	antiviral	?
Alpha Interferon	immunomodulating agent	unknown
cidofovir	nucleotide analogue	conflicting data
Analogues of Camptothecin	DNA topoisomerase I inhibitor, blocks JCV replication in vitro	
HAART	immunorestitution possible indirect antiviral effect	yes
antisense oligonucleotides	binding to JCV DNA	unknown

#### Cytomegalovirus (CMV)

CMV is a DNA containing virus, and a member of the herpesvirus family, which causes disease to reactivation in patients with very low CD4 cell counts, e.g.  $< 50$  cells/ $\mu$ L [104, 105] . Most commonly in AIDS patients, CMV infects the retina and to a lesser extent the GI tract including the colon, esophagus and biliary tract. Neurological disease is less common but is well described. Neurological disease due to CMV may be underestimated as CMV is present in the brain in 12-40% of patients at autopsy but is rarely diagnosed clinically [5, 7, 106-108] . It is

quite common to have a concomitant CNS opportunistic process when CMV disease is diagnosed. This often makes it difficult to determine the amount of disease specifically attributable to CMV. Most patients with neurological CMV disease have been previously diagnosed with CMV disease at another site e.g. retina [106, 109] . In a recent review of the literature of patients with neurologic CMV the median CD4 cell count was 16 cells/ $\mu$ L and 86% of patients had evidence of CMV infection outside of the central nervous system [106] .

Six neurological syndromes due to CMV have been described and are listed in the table.

<b>Neurological CMV Syndromes</b>
1. diffuse micronodular encephalitis
2. ventriculoencephalitis
3. focal parenchymal necrosis
4. mass lesions
5. radiculomyelitis
6. mononeuritis multiplex

**Pathology-** Four pathological lesions of CMV in the CNS have been described by Morgello et. al. [108] : 1. Isolated cytomegalic cells not associated with microglial nodules or inflammation; 2. microglial nodules; 3. focal parenchymal necrosis, characterized by macrophages, axonal swelling, and cells with CMV inclusions; 4. ventriculoencephalitis (VE)- focal or diffuse destruction of the ependymal lining and necrosis of periventricular

parenchymal tissue associated with dense accumulation of cytomegalic cells. Diffuse infection of ependymal and subependymal lining cells is the rule. The clinical significance of isolated cytomegalic cells is not clear and focal parenchymal necrosis appears to be uncommon. Clinically the two major syndromes of CMV encephalitis are diffuse micronodular encephalitis (associated with microglial nodules) and ventriculoencephalitis. Micronodular encephalitis is more common at autopsy and is less commonly associated with symptoms compared to ventriculoencephalitis.

Diffuse micronodular encephalitis is characterized by multifocal, diffusely scattered, micronodular encephalitis. These nodules are aggregates of macrophages and glial cells [108, 110] . Usually there is no inflammatory response. Small microglial nodules and inclusions bearing cytomegalic cells are concentrated in gray matter and widely distributed in cortex, basal ganglia, brain stem and cerebellum [111] . CMV is found primarily in astrocytes, and occasionally in neurons and capillary endothelial cells. Microglial nodules are not specific for CMV as they can also be seen in HIV dementia. However, CMV is suggested by predominant localization in the (sub)cortical gray matter, the absence of giant cells and the occasional finding of intranuclear inclusions in or near the nodules [108, 110] . Although frequently found pathologically the clinical significance is not always clear. Diffuse micronodular encephalitis may present with dementia and thus AIDS Dementia Complex (ADC) is in the differential diagnosis. CMV micronodular encephalitis may follow a more rapid course than ADC.

Pathologically VE is characterized by extensive necrosis of cranial nerve roots and of the periventricular parenchyma and ependymal lining. Clinically VE presents as a rapidly progressive delirium, cranial nerve deficits, nystagmus, and ataxia. Patients often present while receiving maintenance therapy for CMV retinitis. The CSF usually reveals one or more of the following: elevated protein, pleocytosis and hypoglycorrhachia. However normal CSF has been reported. In patients with isolated ventriculoencephalitis the CSF pleocytosis consists mostly of mononuclear cells. In patients with concomitant radiculomyelitis neutrophil predominance is

seen more frequently [106] . CSF pleocytosis ranges from minimal to 18,000 cells [110] . One series had a high number of patients with electrolyte abnormalities due to CMV adrenal insufficiency or volume depletion [107] .

MRI in VE reveals progressive ventricular enlargement, periventricular enhancement and increased periventricular signal on T2 weighted images. VE differs in several respects from diffuse micronodular encephalitis. The onset is more rapid; cranial nerve palsies and nystagmus are common as is simultaneous radiculomyelitis. Diffuse micronodular encephalitis and VE may have different routes of infection. The anatomic distribution of micronodular encephalopathy suggests a hematogenous route, whereas it is likely infection in VE is via CSF through ependymal cells. The periventricular brain is likely invaded via the ependymal cells which line the ventricles.

Diagnosis- Plasma serology is not useful in the diagnosis of CMV disease in AIDS, since the vast majority of HIV-infected patients have acquired CMV early in life and remain seropositive. CMV can rarely be cultured from CSF in patients with encephalitis. The demonstration of intrathecal CMV antibodies is rarely possible, probably due to the poor host immune response [27] . Recent studies have demonstrated the utility of CSF CMV PCR in the diagnosis of CMV neurological disease [112-114] . In published studies the sensitivity of CMV PCR has ranged from 33-100% and the specificity from 42-100%; however, in the majority of studies the sensitivity exceeded 80% and the specificity was greater than 90%. Reasons for variable results among studies include different PCR techniques and different definitions of CMV disease. Some studies used a clinical diagnosis of neurological CMV disease, while others used histology. The CMV viral load appears to be related to the extent of infection and the type of CMV infection. For example patients with polyradiculopathy and/or ventriculoencephalitis appear to have higher levels of CMV in the CSF [115-117] .

Quantitative CMV PCR was found to be useful in gauging response to therapy in a small series [117] . Patients with higher initial CMV DNA viral loads are less likely to become CMV DNA negative following ganciclovir therapy [117] . However, another study did not find a correlation of CSF viral load and clinical response [109] . As in other virally mediated focal CNS diseases in AIDS, PCR has become a very important diagnostic tool for CMV encephalitis.

CMV Treatment- In general patients diagnosed with CMV disease of the CNS have a poor prognosis with death occurring in 4-6 weeks to 7 months [116-118] . Reasons for this are multiple including the advanced immunosuppression of the patients, possible viral resistance, poor penetration of ganciclovir into the CNS, and the fact that some neurological damage may be irreversible. Ganciclovir, the mainstay of treatment for CMV disease outside of the CNS reaches lower concentrations in the CSF compared to serum with CSF concentrations approximately 26-70% of serum levels [111] . Brain parenchymal concentrations of ganciclovir are 38% of serum levels [119] . Clinical responses in patients treated with ganciclovir alone have occasionally been reported [120] , but in general are disappointing [107, 117] .

Since results with ganciclovir alone are poor, other agents have been tried. Cidofovir, a nucleotide analogue with broad activity versus the herpesviruses including CMV has been used successfully in a patient who had failed ganciclovir [91] . Foscarnet, a pyrophosphate analogue, has been also been used. Foscarnet has better penetration of the blood brain barrier compared to

ganciclovir. In two studies CSF foscarnet levels were 27-39% of serum levels, but in a third study CSF levels were 66% of serum levels [111, 121] . There is also evidence of synergy in vitro, when ganciclovir is combined with foscarnet [122, 123] . Combination therapy with foscarnet and ganciclovir has been shown to be more effective than either agent alone in patients with recurrent CMV retinitis and with polyradiculopathy [124, 125] . An open label study of combined foscarnet-ganciclovir therapy in 31 patients with neurological CMV disease was recently reported [109] . Median survival was 94 days, which compares to a median survival of 42 days in a group of historical controls who mostly received CMV monotherapy [106] . Given the poor outcomes with monotherapy combination therapy may be justified; however, prospective randomized data are needed.

### **Cerebrovascular disease**

There appears to be a higher incidence of cerebrovascular disease in HIV, ranging from 0.5-10% [7, 126] . Both cerebral ischemia and hemorrhage have been described with the former being more common. Possible etiologies include a primary HIV vasculitis [127] , the antiphospholipid/ anticardiolipin antibody syndrome, and protein S deficiency, as well as secondary complications such as mycotic aneurysms due to endocarditis in intravenous drug users and vasculitis due to herpetic viral infections and syphilis [128] .

### **Other infections**

Several other infections which may occasionally present with focal lesions in HIV infected patients include *Nocardia*, Varicella-Zoster virus, *Aspergillus*, *Listeria monocytogenes*, syphilis, *Histoplasma capsulatum*, *Cryptococcus neoformans*, and *Mycobacterium Tuberculosis*. The latter three organisms more commonly cause meningitis but may present as a focal process. Patients with *Nocardia* may present with simultaneous pulmonary involvement.

### **Neuroimaging**

MRI is the preferred neuroimaging modality for AIDS patients with focal CNS disease. MRI has greater sensitivity than CT for toxoplasmosis and white matter disease (e.g. PML) and for disease in the posterior fossa. In one study 22% of patients with normal CT scans had abnormal MRI. In another 22% of cases MRI demonstrated an increased number of focal lesions compared to CT [129] . In most cases white matter diseases such as ADC and PML can be differentiated from toxoplasmosis and lymphoma based on clinical, laboratory and radiographic data. While certain radiographic characteristics favor lymphoma over toxoplasmosis, e.g. a solitary lesion, location adjacent to the ventricle, subependymal spread, and homogenous rather than ring enhancement, consider overlap occurs. In many cases the constellation of symptoms, physical findings, laboratory studies, and neuroimaging studies is not sufficiently specific to reliably differentiate toxoplasmosis from CNS lymphoma [53, 128, 130, 131] . Another factor which lowers the diagnostic utility of routine neuroimaging techniques in AIDS patients is the fact that oftentimes more than one process occurs simultaneously.

### **The Role of Brain Biopsy**

Studies have also demonstrated the relatively poor predictive acumen of physicians in determining the etiology of brain lesions in HIV-infected patients. In the largest study, physicians' preoperative diagnosis was incorrect in 34% of cases [18]. In another study the clinical diagnosis was incorrect 48% of the time [132]. Due to the limitations of noninvasive techniques, tissue diagnosis by means of brain biopsy remains the gold standard for diagnosis of focal brain lesions in patients with AIDS.

Several retrospective series, consisting of over 600 patients, have evaluated the role of brain biopsy in AIDS patients with intracranial mass lesions (see table below) [18, 61, 132-140]. Overall, the diagnostic yield is high (70-96%). Either craniotomy, ultrasound guided or CT/MRI guided stereotactic brain biopsy can be done. However, in practice the most common technique is CT or MRI guided stereotactic biopsy, since it is associated with significantly lower morbidity than craniotomy and provides adequate tissue in most cases. A definitive diagnosis was determined in greater than 90% of patients undergoing biopsy in most studies. Importantly, diagnoses other than lymphoma, PML or toxoplasmosis are identified in up to 18% of biopsies. Such diagnoses include non-HIV related brain tumors and other infections (CMV, mycobacterial, nocardia, etc). Interestingly, in the largest study, six percent of patients had more than one diagnosis from biopsy of a single brain lesion [18]. Since lymphoma lesions often have central necrosis, in order to avoid non-diagnostic biopsies, it is suggested that the enhancing rim of the lesion be the biopsy target, as this may represent the only viable lymphoma tissue [18].

**TABLE. Brain biopsy in AIDS**

Series (n)	Lymphoma	PML	Toxo	Other	Definitive Diagnosis	Major Morbidity*†	Mortality#
Viswanathan (13)	31%	23%	38%	15%	85%	8%	0
Chappell (25)	36%	24%	8%	12%	80%	4%	0
Levy (50)	28%	28%	26%	18%	96%	8%	0
Feiden (23)	39%	22%	30%	4%	88%	0	8.7%
d'Armino Monforte (20)	15%	35%	25%	15%	70%	5%	0
Iacoangelli (12)	50%	25%	0%	17%	92%	8.3%	0
Luzazzati (26)	46%	23%	15%	8%	92%	11.5%	0
Zimmer (25)	40%	8%	40%	4%	92%	0	0
Hornef (26)	42%	15%	23%	12%	96%	4%	4%
Antinori (158)	51%	17%	6%	14%	86%	3.7%	3.1%
Gildenberg (251)	33%	30%	15%	16%	94%	3.2%	2.8%

\* Defined as hemorrhage or permanent neurological deficits.

† Does not include death.

# Biopsy related Mortality (death related to biopsy complication within 30 days of biopsy)

In general, the morbidity of brain biopsy has been low (table). The major morbidity relates to the occurrence of hemorrhage at the operative site, which has mostly occurred in cases of lymphoma. Of the studies published to date major morbidity resulting in hemorrhage or

permanent neurologic deficits has ranged from 0-12%. The incidence of death related to the procedure has ranged from 0-9%, although in 5 of 8 studies no deaths occurred.

Unfortunately, the procedure is invasive and places the surgical personnel at risk of occupational acquisition of HIV. Thus, other less invasive methods of diagnosis have been sought in recent years. Newer laboratory techniques have been discussed above. New radiographic techniques will be reviewed below.

Making a timely and accurate diagnosis of focal CNS lesions in patients with AIDS is important because management of the different pathological processes differs considerably. However, determining the specific cause of focal CNS disease in this patient population can be difficult since the clinical and radiographic presentation of toxoplasmic encephalitis and primary brain lymphoma, the two most common causes of focal brain disease in AIDS, overlap considerably [53, 128, 130]. While it is acceptable to make an empiric diagnosis of toxoplasmic encephalitis based on the Toxoplasma serology and an empiric response to appropriate therapy, brain biopsy has traditionally been the gold standard for the diagnosis of primary brain lymphoma.

### **Functional Neuroimaging**

#### **SPECT Thallium-201**

Thallium-201 (Tl-201) brain single photon emission computerized tomography (SPECT) has been used to aid in the diagnosis of brain tumors for over 20 years. More recently it has been used to differentiate CNS lymphoma from infectious causes of brain lesions (most commonly toxoplasmic encephalitis) in patients with AIDS. Tl-201 (thallous chloride), a radioisotope, is a potassium analog. The most likely mechanism for the increased accumulation of Tl-201 in tumors is the  $\text{Na}^+/\text{K}^+$  ATPase pump located on the cell membrane [141-144]. Tumor cells, which have a high rate of metabolic activity accumulate more Tl-201 (via active transport) than normal surrounding normal tissue. Several other mechanisms have been proposed for the increased accumulation of Tl-201 in tumors including increased regional blood and increased cell membrane permeability [143, 144]. In contrast to tumors, areas of infection or abscess which contain necrotic tissue generally do not take up increased amounts of radioisotope.

SPECT Tl-201 scans can be interpreted in two ways, e.g., qualitative visual interpretation or quantitative lesion uptake ratios. In the former method, the radiologist after reviewing the CT or MRI scan compares the region of interest corresponding to the mass lesion with the surrounding and/or contralateral brain. An area which demonstrates increased thallium retention compared to the surrounding brain is considered positive and thus a diagnosis of malignancy (lymphoma) is presumed. On the other hand, lesions which do not retain thallium are considered negative and are consistent with a diagnosis other than malignancy. The quantitative method calculates a lesion uptake ratio. In this method a region of interest is drawn around the lesion and then mirrored on either the normal contralateral brain or the scalp. The uptake ratio is calculated by dividing the lesion activity by the activity of either the contralateral brain or the contralateral scalp.

**Table. SPECT Thallium-201 Studies in AIDS**

Study (first author)	n	M e t h o d Interpretation	o f Sensitivity	Specificity
O'Malley	13	subjective	100%	86%
Ruiz	37	uptake ratios	100%	100%
Lorberboym	18	uptake ratios	100%	90%
D'Amico	37	uptake ratios	75%	96%
Lorberboym	49	subjective	96%	76%
De La Pena	36	uptake ratios	83%	96%
Lee	21	subjective	100%	80%
Miller	32	uptake ratios	55%	100%
Antinori	31	uptake ratios	92%	89%
Skiest	38	uptake ratios	86%	83%
<b>Total</b>	<b>312</b>		<b>92%†</b>	<b>89%†</b>

† weighted mean

Several studies have evaluated the utility of Tl-201 SPECT in distinguishing cerebral lymphoma from toxoplasmic encephalitis in patients with AIDS (table) [131, 145-156] . The initial studies which evaluated the role of SPECT Tl-201 for the diagnosis of diagnosing CNS lymphoma in AIDS patients were very promising [151, 152] . O'Malley et al., reported that six of seven AIDS patients with CNS mass lesions who had increased Thallium-201 uptake on SPECT had a diagnosis of lymphoma, while none of six patients lacking thallium uptake were diagnosed with lymphoma [151] . Ruiz et al. reported that all twelve patients with increased Thallium-201 uptake had a tissue diagnosis of lymphoma, while all 25 patients without increased uptake had an infectious diagnosis [152] . In subsequent reports however, the diagnostic accuracy of this technique has been lower than initially reported [131, 146, 147, 149, 150, 153, 154, 156-159] . Both false positive and false negative results have been reported.

Lorberboym et al. evaluated Tl-201 SPECT in AIDS in two studies. In an initial retrospective study of 18 patients Tl-201 SPECT had a sensitivity of 100% and specificity of 90% [149] . D'Amico studied 37 AIDS patients with contrast enhancing CNS lesions on CT or MRI [146] . Using three different methods of calculating lesion to background uptake indices the best results they obtained were 75% sensitivity and 96% specificity. In a study conducted at Parkland Hospital, Skiect et al. recently reported a lower sensitivity of 86% and a specificity of 83% for SPECT Tl-201 [153] .

Recently several groups have reported modifications of SPECT Tl-201 scanning to improve the diagnostic accuracy. A second study by Lorberboym and colleagues of 49 AIDS patients with focal lesions, found immediate Tl-201 SPECT scanning to have a sensitivity of 96%, and a specificity of 76%. By looking at delayed thallium uptake in lesions (at three hours) compared to early uptake they calculated a retention index and were able to differentiate false positive scans from true positive scans, which improved the specificity from 76% to 100% [150] . Lee et al. used sequential thallium and gallium scintigraphy which they found useful in determining whether thallium negative lesions were infectious (gallium avid) or non-infectious (negative gallium) [154] . Technetium-99m sestamibi, another radioisotope, has been utilized in SPECT



scans and was found to have similar sensitivity and specificity to thallium-201, but with higher lesion to normal tissue ratios [147] . However, validation studies are needed.

The accuracy of SPECT Tl-201 can be affected by several factors including size of the lesion, the grade of the malignancy, the presence of necrotic areas in the tumor [147] , and location of lesions [147, 151] . False negative results are more likely with smaller lesions (< 6-8mm), which are below the resolution of the gamma camera, necrotic and hemorrhagic tumors, and lesions of low grade malignancy [147, 156, 157] . In addition, tumors located near the base of the skull may be obscured by the normally high activity in this region [151, 156] . In contrast, non-specific uptake has occasionally been demonstrated in lesions other than lymphoma such as infections for reasons which are not clear. Corticosteroids do not appear to diminish the sensitivity of SPECT Tl-201 [157] . False positive results may be less likely using lesion uptake ratios instead of qualitative assessment [156] .

Another problem is that patients with AIDS may have several intracranial lesions, with more than one etiology [18] . Thus, in the patient with multiple lesions some lesions may take up Tl-201 while others do not. In such cases the SPECT results may be difficult to interpret; it will not be clear whether the lesions represent lymphoma, another diagnosis or two diagnoses. Thus, SPECT Tl-201 is a useful diagnostic test in patients with focal lesions, however, limitations do exist, and information obtained as part of the test should be used in conjunction with other data to improve diagnostic accuracy.

### **Positron Emission Tomography (PET)**

Like SPECT T-201, PET scanning is based on the increased cell division and metabolism characteristic of malignant cells. PET uses a radiopharmaceutical, most commonly <sup>18</sup> FDG (18-fluorodeoxyglucose), which enters the cell and competes for the enzyme hexokinase by the same mechanism as glucose. Malignant cells, which have an enhanced rate of glycolysis take up the glucose tracer at a higher rate than surrounding non-malignant tissue. Tumors thus appear hypermetabolic or "hot" on PET scan compared to surrounding normal tissue. The degree of metabolic activity can also be used to estimate the tumor grade. Scans can be assessed visually (subjectively), semiquantitatively, or quantitatively (objectively). Regions of interest are drawn around the lesion and then mirrored on contralateral normal brain. Lesion activity is then measured with the contralateral cortex providing the reference point.

### **PET in AIDS**

Relatively few studies of PET in AIDS patients with intracranial mass lesions have been published [160-165] . Hoffman et al, studied 11 patients with AIDS and CNS lesions, who were either receiving therapy for toxoplasmosis or had failed such therapy, or had undergone brain biopsy [160] . Based on both qualitative and semiquantitative analysis of metabolic activity, lesions of lymphoma could be differentiated from non-malignant lesions (lymphoma semiquantitative score = 1.8 versus non-lymphoma semiquantitative score = 0.88). In the one patient with PML lesion activity was intermediate between malignant and toxoplasmosis. Although interesting this study was small and all patients were receiving therapy when PET was performed, which could have affected the results.



Villringer et al. studied 11 patients with CNS mass lesions [165] . They found the lowest activity in patients with toxoplasmosis and the highest activity in patients with lymphoma, with no overlap. Heald et al. conducted a study of PET in 18 AIDS patients with CNS mass lesions [163] . They used several methods to assess lesion activity including a qualitative visual score and semi-quantitative lesion to contralateral brain uptake ratios. They found that PET was able to differentiate lesions of toxoplasmosis from those of lymphoma. However, two of two patients with PML had lesion uptake ratios that were relatively hypermetabolic, which resulted in overlap with the lymphoma patients.

O'Doherty et al. studied 23 HIV-infected patients with CNS lesions with PET [164] . They found that lesions with low metabolic activity were either toxoplasmosis or PML and all lymphoma lesions were associated with high metabolic activity. No overlap was seen between patients with infections and those with lymphoma.

Pierce et al prospectively studied 20 patients with AIDS and contrast enhancing brain lesions by either CT or MRI. All patients underwent PET scanning. PET lesions were graded as either hypometabolic or hypermetabolic depending on their activity relative to white matter. They found all toxoplasma lesions were hypometabolic and all lymphoma lesions were hypermetabolic as expected. However, of two patients with PML, one had hypometabolic lesions and the other had hypermetabolic lesions [162] .

Although it appears promising there are a number of problems with PET, which prevent its widespread use. First, the technology is not yet widely available and in many cases the cost of the test is prohibitive (approximately \$2500). Second, for reasons which are not clear not PML may occasionally demonstrate increased metabolic activity, e.g. look like lymphoma. However, in most instances the MRI appearance of PML should be sufficiently different from lymphoma. Finally, very small lesions may be below the level of detection of PET.

### **MR Spectroscopy (MRS)**

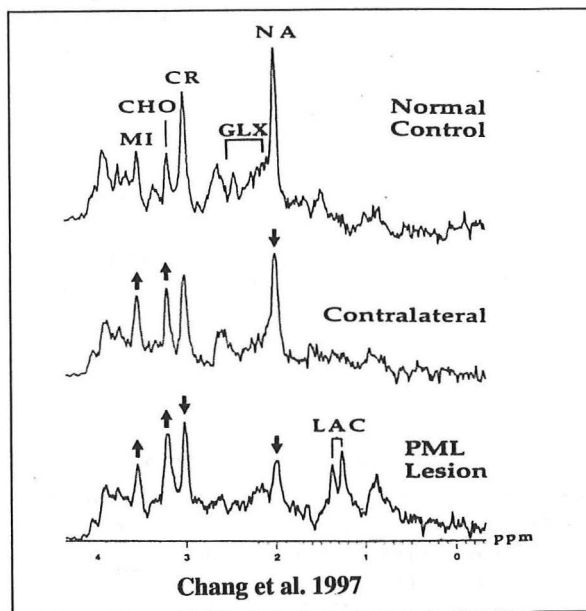
Proton magnetic resonance spectroscopy (MRS) is a relatively new technique, which combines MRI with spectroscopy. This non-invasive technique allows in vivo measurements of various brain metabolites. Metabolites are identified by their frequency, e.g., position in the spectrum, which is expressed as a shift in the frequency in parts per million (ppm) relative to a standard [166] . In non-AIDS patients altered levels of certain metabolites have been associated with various disease states of the central nervous system including ischemia, multiple sclerosis, Parkinson's disease, Alzheimer's dementia, and tumors. The metabolites which are commonly measured include N-acetyl aspartate (NAA), choline-containing compounds (CHO), total creatine (CR), myoinositol (MI), glutamate, lipids, and lactate.

To perform MRS a spectral volume of interest or voxel is placed within a focal lesion seen on MRI. A second voxel is then placed in normal appearing brain parenchyma in the contralateral brain. The lesion voxel is then compared to contralateral brain voxel. Metabolite peaks are then analyzed with a computer software program. Some studies report absolute peaks while others report the metabolite peaks compared to a reference such as creatine.

Briefly, altered levels of the various metabolites have been interpreted as follows. NAA is a neuron marker and decreased levels have been associated with neuronal or axonal injury, such as

in AIDS dementia. In addition, low levels would be expected in a brain abscess (toxoplasma or other). Choline containing compounds (free choline, phosphocholine, glycerophosphocholine etc.) are constituents of cell membranes and myelin. Increased levels have been associated with increased turnover of myelin, as seen in demyelinating conditions such as PML or cell membranes (tumor) and low levels have been associated with loss of cells (infection). Lactate levels are high in abscess and tumor due to ischemia as well as a decreased rate of clearance from the lesion. Lipid peaks are thought to represent degradation products of phospholipids and sphingomyelin as is seen in the breakdown of myelin and membranes. Creatine and phosphocreatine are thought to be present due to cellular metabolism.

Relatively specific chemical profiles occur in patients with different pathological conditions. While studies in AIDS patients with focal CNS disease have demonstrated typical patterns for each disease state, as with other radiographic techniques overlap may occur. In general toxoplasmic lesions demonstrate elevated lactate and lipid peaks with depletion of normal metabolites. In contrast lesions due to lymphoma tend to have elevated choline peaks and mildly to moderately elevated lactate and lipid peaks. PML lesions generally have low NAA, high CHO and lipids and variable lactate levels. However, overlap does occur among the different pathologic entities; for example, some lymphomas with central necrosis may have spectra similar to toxoplasmosis.



Chang et al studied MRS in 35 AIDS patients with focal brain lesions [167]. They found that MRS could differentiate toxoplasmosis from lymphoma, PML and cryptococcoma with 84%-94% accuracy. Significant differences in the measured metabolites (NAA, CR, CHO, MI) were noted in the four groups. Lesions of toxoplasmosis were depleted of all measured metabolites except lactate and lipid. In contrast lesions of lymphoma were associated with an elevated or normal CHO peak with other metabolites relatively mildly depleted. Lesions in patients with

PML had increased CHO levels and low levels of other metabolites. Lesions in patients with cryptococcomas were characterized by depleted NAA and low lactate peaks.

Chinn et al., were unable to replicate the findings of Chang et. al. In a MRS study of 26 AIDS patients with focal CNS lesions they did not find significant differences in any of the ratios of metabolites when comparing patients with presumed or proven toxoplasmosis to patients with presumed or proven lymphoma [168]. In another study, Simone et al. found metabolite abnormalities in all lesions types but did not find MRS of utility in the differentiation of toxoplasmosis from lymphoma [169]. In contrast to Chang et al, Simone found a lactate signal in most patients with PML lesions. Other studies of PML confirmed the high CHO levels and low levels of other metabolites but also reported relatively high levels of lactate and lipids which is in contrast to the earlier study by Chang [170, 171].

Reasons for the discrepancy between these studies may include different techniques and different methods of analysis. For example Chinn and Simone measured ratios of various metabolites as compared to a reference metabolite whereas Chang did not. Another problem with MRS is that the comparator which is usually the contralateral brain is not necessarily normal. In fact, studies have demonstrated loss of NAA in many patients presumably due to the neuronal loss associated with HIV infection of the brain [172]. Before MRS is adopted for widespread use, it needs to be better standardized and larger validation studies are needed.

**Radiologic Patterns of CNS Mass Lesions in AIDS**

	Toxoplasmosis	Lymphoma	PML
<b>MRI</b>			
<b>Enhancement pattern</b>	Yes ring	Yes homogenous or ring	No enhancement
<b>Edema</b>	Yes	Yes	No
<b>SPECT Tl-201</b>	Cold	Hot	Cold
<b>PET</b>	Hypometabolic	Hypermetabolic	Hypometabolic?
<b>MRS</b>	↑ Lactate, NAA ↓	CHO ↑ or ↓	CHO ↑, Lactate ↑ or ↓, lipids ↑ or ↓,

NAA- N-acetyl aspartate, CHO- choline-containing compounds, Cr- creatine,

Functional neuroimaging has led to advances in diagnosis in many areas of medicine including the AIDS patient with a focal brain lesion. Each modality, SPECT-Tl-201, PET, and MRS has limitations, however and none provide a tissue diagnosis. None of these tests should be relied on in isolation, because both false positive and false negative results may occur on occasion. Specific expertise is required for interpretation of these tests and rigid diagnostic criteria (especially for SPECT and MRS) have not yet been agreed upon. These tests are also costly especially PET. However, when used with other criteria including toxoplasma serology, and PCR they provide valuable diagnostic information.

The polymerase chain reaction has led to significant advances in the diagnosis of focal brain disease in patients with AIDS. The highest utility has been demonstrated for diseases caused by viruses. These include the herpesviruses CMV, HSV, VZV, and EBV, as well as the JC virus. PCR is also useful for the diagnosis of *Mycobacterium tuberculosis*, although the precise

sensitivity and specificity in Tb is unknown. PCR may be useful for monitoring CSF HIV viral load in patients with HIV dementia, as there is some correlation between HIV load and stage of dementia. PCR has been less useful for the diagnosis of toxoplasmosis and neurosyphilis. A recent small study of demonstrated the utility of a multiplex PCR (for toxoplasmosis and lymphoma) for diagnosis of AIDS related focal CNS lesions. [173] .

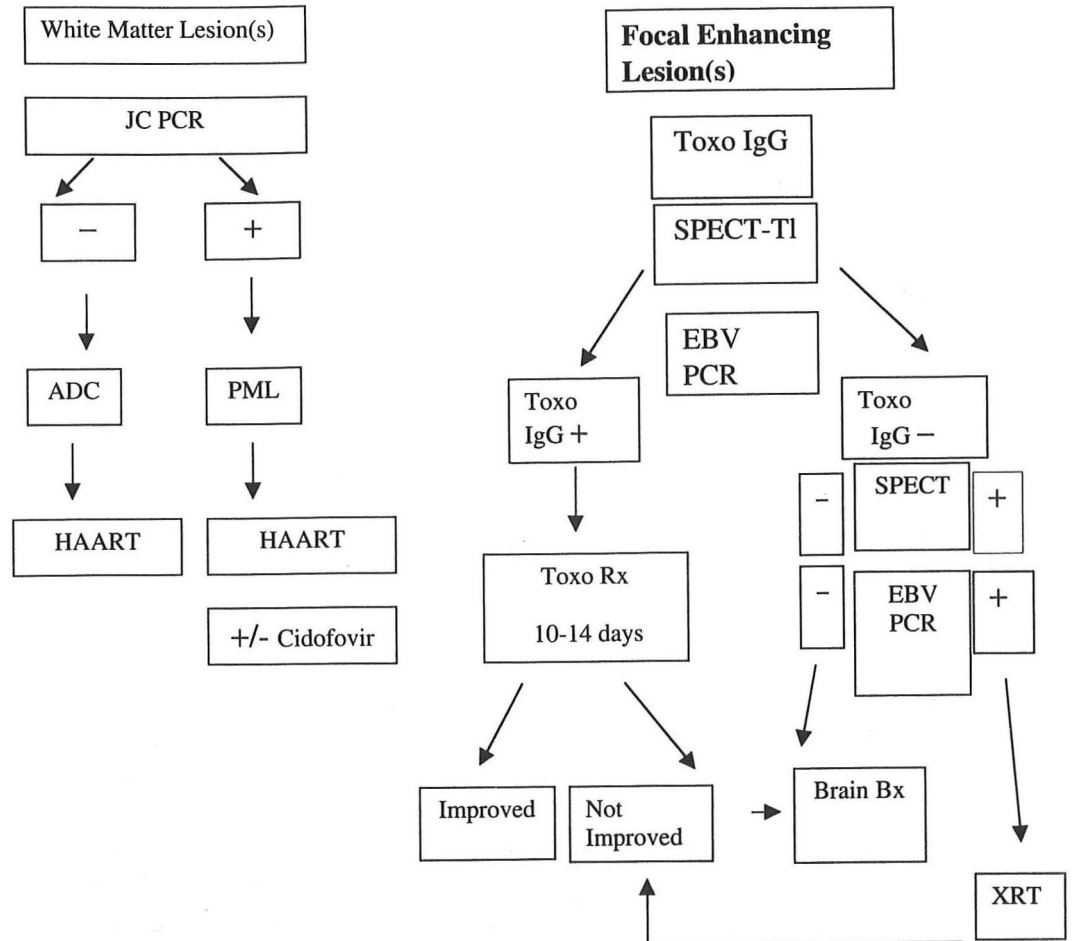
CSF PCR has some limitations. In some cases the test may too sensitive. For example, patients with low levels of CMV in CSF may have clinically insignificant disease e.g. isolated cytomegalic cells. Furthermore, it is theoretically possible that CSF may become contaminated with latent virus extracted from peripheral cells in the CSF. Development of quantitative PCR techniques may improve the specificity in such cases, by allowing clinically significant cut-off values. A practical problem with CSF PCR is the fact that it may not be safe to obtain spinal fluid in all patients, e.g. patients at risk of herniation.

Algorithm based approaches for the management of AIDS patients with intracranial mass lesions have been suggested and guidelines have been proposed by the American Academy of Neurology and others [22, 126, 145] . These algorithms incorporate clinical criteria, laboratory (toxoplasma serology) and radiographic criteria (single versus several lesions), and response to empiric toxoplasma therapy, as well as newer techniques including CSF PCR and functional neuroimaging.

At Parkland Hospital we instituted an local algorithm which has been used since January 1999. Our algorithm incorporates radiographic findings (enhancement or not), serum toxoplasma serology, SPECT Tl-201, and CSF PCR for JC virus and EBV. Patients with positive serum toxoplasma serology, negative SPECT Tl-201, and negative EBV PCR receive empiric treatment directed at toxoplasmosis. Patients with both positive EBV PCR and SPECT Tl-201 receive empiric brain radiation for presumptive lymphoma. Brain biopsy is reserved for patients in whom the above data is discordant and for patients treated empirically for toxoplasmosis who do not respond to two weeks of therapy. A similar approach to diagnosis and management has recently been validated in a prospective study from Italy [145] . In this study combining results of SPECT Tl-201 and EBV PCR resulted in a high degree of diagnostic accuracy.

Although newer treatments have improved the outcome for many individuals with HIV, neurologic complications will continue to be an important problem for this group of patients. New diagnostic techniques including PCR based diagnostic assays and functional neuroimaging have improved diagnostic accuracy in patients with focal CNS disease. These new diagnostic tests now allow for the empiric treatment of some patients without the need for brain biopsy. However, further modifications of these tests and larger validation studies are needed. Furthermore it should be remembered that a significant minority of AIDS patients will present with a focal brain mass due to an unusual cause, which is not readily diagnosed without tissue. Brain biopsy remains the most definitive diagnostic modality, and there continues to be a subset of patients whom will benefit from biopsy.

## Parkland CNS AIDS Algorithm



## REFERENCES

1. Centers for Disease Control and Prevention. HIV/AIDS Surveillance Report. 1999;11:1-44
2. Simpson D, Berger J. Neurologic manifestations of HIV infection. Med Clin North Am 1996;80:1363-94
3. Janssen RS. Epidemiology and Neuroepidemiology of Human Immunodeficiency Virus Infection. In: J.R. B, Levy RM, eds. AIDS and the Nervous System. Second ed. Philadelphia: Lippincott-Raven Publishers, 1997:13-37
4. Levy R, Bredezen D, Rosenblum M. Neurological manifestations of the acquired immunodeficiency syndrome (AIDS): Experience at UCSF and review of the literature. J Neurosurg 1985;62:475-95
5. Burns D, Risser R, White C. The neuropathology of human immunodeficiency virus infection. Arch Pathol Lab Med 1991;115:1112-24

6. Masliah E, DeTeresa RM, Mallory ME, Hansen LA. Changes in pathological findings at autopsy in AIDS cases for the last 15 years. *AIDS* 2000;14:69-74
7. Kure K, J.F. L, Lyman WD, et al. Human immunodeficiency virus 1 infection of the nervous system: An autopsy study of 268 adult, pediatric, and fetal brains. *Hum Pathol* 1991;22:700-10
8. Luft B, Remington J. AIDS Commentary: toxoplasmic encephalitis. *J Infect Dis* 1988;157:1-6
9. Ammassari A, Scoppettuolo G, Murri R, Pezzotti P, Cingolani A, Del Borgo C, De Luca A, Antinori A, Ortona L. Changing disease patterns in focal brain lesion-causing disorders in AIDS. *J Acquir Immune Defic Syndr Hum Retrovirol* 1998;18:365-71
10. Cohen BA. Neurologic manifestations of toxoplasmosis in AIDS. *Semin Neurol* 1999;19:201-11
11. Mariuz P, Bosler E, Luft B. Toxoplasmosis. In: Berger J, Levy R, eds. *AIDS and the Nervous System*. 2nd ed. Philadelphia: Lippincott-Raven Publishers, 1997:641-59
12. Porter S, Sande M. Toxoplasmosis of the central nervous system in the acquired immunodeficiency syndrome. *New Engl J Med* 1992;327:1643-1648
13. Renold C, Sugar A, Chave J, Perrin L, Delaville J, Pizzolato G, Burkhard P, Gabriel V, Hirschel B. Toxoplasma encephalitis in patients with the acquired immunodeficiency syndrome. *Medicine* 1992;71:224-239
14. Luft B, Hafner R, Korzun A, et al. Toxoplasmic encephalitis in patients with the acquired immunodeficiency syndrome. *New Engl J Med* 1993;329:995-1000
15. Laing RB, Flegg PJ, Brett RP, Leen CL, Burns SM. Clinical features, outcome and survival from cerebral toxoplasmosis in Edinburgh AIDS patients. *Int J STD AIDS* 1996;7:258-64
16. Luft B, Remington J. Toxoplasmic encephalitis in AIDS. *Clin Infect Dis* 1992;15:211-22
17. Vyas R, Ebright J. Toxoplasmosis of the spinal cord in a patient with AIDS: Case report and review. *Clin Infect Dis* 1996;23:1061-65
18. Gildenberg PL, Gathe JC, Jr., Kim JH. Stereotactic biopsy of cerebral lesions in AIDS. *Clin Infect Dis* 2000;30:491-9
19. Grant I, Gold J, Rosenblum M, Niedzwiecki D, Armstrong D. *Toxoplasma gondii* serology in HIV-infected patients: the development of central nervous system toxoplasmosis in AIDS. *AIDS* 1990;4:519-21
20. Raffi F, Aboulker J, Michelet C, et al. A prospective study of criteria for the diagnosis of toxoplasmic encephalitis in 186 AIDS patients. *AIDS* 1997;11:177-184
21. Hellerbrand C, Goebel F, Disko R. High predictive value of *Toxoplasma gondii* IgG antibody levels in HIV-infected patients for diagnosis of cerebral toxoplasmosis. *Eur J Clin Microbiol Infect Dis* 1996;15:869-72
22. Antinori A, Ammassari A, De Luca A, et al. Diagnosis of AIDS-related focal brain lesions: A decision-making analysis based on clinical and neuroradiologic characteristics combined with polymerase chain reaction assays in CSF. *Neurology* 1997;48:687-94
23. Wanke C, Tuazon C, Kovacs A, Dina T, et al. *Toxoplasma* encephalitis in patients with acquired immune deficiency syndrome: diagnosis and response to therapy. *Am J Trop Med Hyg* 1987;36:509-16
24. Potasman I, Resnick L, Luft B, Remington J. Intrathecal production of antibodies against *Toxoplasma gondii* in patients with toxoplasmic encephalitis and the acquired immunodeficiency syndrome (AIDS). *Ann Intern Med* 1988;108:49-51
25. Wong B, Gold J, Brown A, Lange M, et al. Central-nervous-system toxoplasmosis in homosexual men and parenteral drug abusers. *Ann Intern Med* 1984;100:36-42
26. Novati R, Castagna A, Morsica G, Vago L, et al. Polymerase chain reaction for *Toxoplasma gondii* DNA in the cerebrospinal fluid of AIDS patients with focal brain lesions. *AIDS* 1994;8:1691-94
27. Cinque P, Scarpellini P, Vago L, Linde A, Lazzarin A. Diagnosis of central nervous system complications in HIV-infected patients: cerebrospinal fluid analysis by the polymerase chain reaction. *AIDS* 1997;11:1-17
28. Gianotti N, Cinque P, Castagna A, Novati R, et al. Diagnosis of toxoplasmic encephalitis in HIV-infected patients. *AIDS* 1997;11:1529-30
29. Schoondermark-van de Ven E, Galama J, Kraaijeveld C, van Druten J, Meuwissen J, Melchers W. Value of the polymerase chain reaction for the detection of *Toxoplasma gondii* in cerebrospinal fluid from patients with AIDS. *Clin Infect Dis* 1993;16:661-6
30. Lamoril J, Molina J-M, Gouvello Ad, Garin Y, et al. Detection by PCR of *Toxoplasma gondii* in blood in the diagnosis of cerebral toxoplasmosis in patients with AIDS. *J Clin Pathol* 1996;49:89-92
31. Dannemann B, McCutchan J, Israelski D, Antoniskis D, Leport C, Luft B, Nussbaum J, Clumeck N, Morlat P, et al. Treatment of Toxoplasmic encephalitis in patients with AIDS: A randomized trial comparing

- pyrimethamine plus clindamycin to pyrimethamine plus sulfadiazine. *Annals of Internal Medicine* 1992;116:33-43
32. Katlama C, Wit SD, O'Doherty E, Glabeke MV, et al. Pyrimethamine-clindamycin vs. pyrimethamine-sulfadiazine as acute and long-term therapy for toxoplasmic encephalitis in patients with AIDS. *Clin Infect Dis* 1996;22:268-75
33. Leport C, Raffi F, Matheron S, Katlama C, et al. Treatment of central nervous system toxoplasmosis with pyrimethamine/sulfadiazine combination in 35 patients with the acquired immunodeficiency syndrome. *Am J Med* 1988;84:94-00
34. Araujo F, Guptill D, Remington J. Azithromycin, a macrolide antibiotic with potent activity against *Toxoplasma gondii*. *Antimicrob Agents Chemother* 1988;32:755-57
35. Araujo F, Huskinson J, Remington J. Remarkable in vitro and in vivo activities of the hydroxynaphthoquinone 566C80 against tachyzoites and tissue cysts of *Toxoplasma gondii*. *Antimicrob Agents Chemother* 1991;35:293-99
36. Godofsky E. Treatment of presumed cerebral toxoplasmosis with azithromycin. *N Engl J Med* 1994;330:575-76
37. Katlama C, Mouthon B, Gourdon D, Lapierre D, et al. Atovaquone as long-term suppressive therapy for toxoplasmic encephalitis in patients with AIDS and multiple drug intolerance. *AIDS* 1996;10
38. Lacassin F, Schaffo D, Perronne C, Longuet P, et al. Clarithromycin-minocycline combination as salvage therapy for toxoplasmosis in patients infected with human immunodeficiency virus. *Antimicrob Agents Chemother* 1995;39:276-77
39. Guex A, Radziwill A, Bucher H. Discontinuation of secondary prophylaxis for toxoplasmic encephalitis in human immunodeficiency virus infection after immune restoration with highly active antiretroviral therapy. *CID* 2000;30:602-3
40. Goedert JJ, Cote TR, Virgo V, Scoppa SM, Kingma DW, Gail MH, Jaffe ES, Biggar RJ. Spectrum of AIDS-associated malignant disorders. *Lancet* 1998;351:1833-39
41. Beral V, Peterman T, Berkelman R, Jaffe H. AIDS-associated non-Hodgkin lymphoma. *Lancet* 1991;337:805-9
42. Cote TR, Manns A, Hardy CR, Yellin FJ, Hartge P. Epidemiology of brain lymphoma among people with or without acquired immunodeficiency syndrome. AIDS/Cancer Study Group. *J Natl Cancer Inst* 1996;88:675-9
43. McArthur J. Neurologic manifestations of AIDS. *Medicine* 1987;66:407-37
44. Grulich AE. AIDS-associated non-Hodgkin's lymphoma in the era of highly active antiretroviral therapy. *J Acquir Immune Defic Syndr* 1999;21 Suppl 1:S27-30
45. Ciacci JD, Tellez C, VonRoenn J, Levy RM. Lymphoma of the central nervous system in AIDS. *Semin Neurol* 1999;19:213-21
46. Tellez C, VonRoenn J, Levy RM. Neoplasms of the central nervous system in the acquired immunodeficiency syndrome. In: Berger J, Levy R, eds. *AIDS and the Nervous System*. Philadelphia: Lippincott-Raven, 1997:705-720
47. Fine HA, Mayer RJ. Primary central nervous system lymphoma. *Ann Intern Med* 1993;119:1093-104
48. Baumgartner JE, Rachlin JR, Beckstead JH, Meeker TC, Levy RM, Wara WM, Rosenblum ML. Primary central nervous system lymphomas: natural history and response to radiation therapy in 55 patients with acquired immunodeficiency syndrome. *J Neurosurg* 1990;73:206-11
49. Wang C, Snow J, Su D. Lymphoma associated with HIV infection. *Mayo Clin Proc* 1995;70:665-672.
50. Gaidano G, Carbone A, Dalla-Favera R. Pathogenesis of AIDS related lymphomas: Molecular and histogenetic heterogeneity. *Am J Path* 1998;152:623-30
51. Bower M, Fife K, Sullivan A, Kirk S, Phillips RH, Nelson M, Gazzard BG. Treatment outcome in presumed and confirmed AIDS-related primary cerebral lymphoma. *Eur J Cancer* 1999;35:601-604
52. Chamberlain MC, Kormanik PA. AIDS-related central nervous system lymphomas. *J Neurooncol* 1999;43:269-76
53. So U, Beckstead J, Davis R. Primary central nervous system lymphoma in Acquired Immune Deficiency Syndrome: A clinical and pathological study. *Ann Neurol* 1986;20:566-72
54. Nuckols JD, Liu K, Burchette JL, McLendon RE, Traweek ST. Primary central nervous system lymphomas: a 30-year experience at a single institution. *Mod Pathol* 1999;12:1167-73
55. Goldstein JD, Dickson DW, Moser FG, Hirschfeld AD, Freeman K, Lena JF, Kaplan B, Davis L. Primary central nervous system lymphoma in acquired immune deficiency syndrome. A clinical and pathologic study with results of treatment with radiation. *Cancer* 1991;67:2756-65



56. Cingolani A, De Luca A, Larocca LM, Ammassari A, Scerrati M, Antinori A, Ortona L. Minimally invasive diagnosis of acquired immunodeficiency syndrome related primary central nervous system lymphoma. *J Natl Cancer Inst* 1998;90:364-9.
57. Cinque P, Vago L, Dahl H, Brytting M, Rosa Terreni M, Fornara D, Racca S, Castagna A, D'Arminio Monforte A, Wahren B, Lazzarin A, Linde A. Polymerase chain reaction on cerebrospinal fluid for diagnosis of virus-associated opportunistic diseases of the central nervous system in HIV-infected patients. *AIDS* 1996;10:951-58.
58. Weber T. Cerebrospinal fluid analysis for the diagnosis of human immunodeficiency virus-related neurologic diseases. *Semin Neurol* 1999;19:223-33.
59. Antinori A, Cingolani A, De Luca A, Gaidano G, Ammassari A, Larocca LM, Ortona L. Epstein-Barr virus in monitoring the response to therapy of acquired immunodeficiency syndrome-related primary central nervous system lymphoma. *Ann Neurol* 1999;45:259-61.
60. Donahue BR, Sullivan JW, Cooper JS. Additional experience with empiric radiotherapy for presumed human immunodeficiency virus-associated primary central nervous system lymphoma. *Cancer* 1995;76:328-32.
61. Skolasky RL, Dal Pan GJ, Olivi A, Lenz FA, Abrams RA, McArthur JC. HIV-associated primary CNS lymphoma: morbidity and utility of brain biopsy. *J Neuro Sci* 1999;163:32-8.
62. Jacomet C, Girard PM, Lebrette MG, Farese VL, Monfort L, Rozenbaum W. Intravenous methotrexate for primary central nervous system non-Hodgkin's lymphoma in AIDS. *AIDS* 1997;11:1725-30.
63. McGowan JP, Shah S. Long-term remission of AIDS-related primary central nervous system lymphoma associated with highly active antiretroviral therapy. *AIDS* 1998;12:952-4.
64. Racz L, Cabral L, Cai JP, Landy H, Sfakianakis G, Byrne GE, Jr., Hurley J, Scerpella E, Jayaweera D, Harrington WJ, Jr. Treatment of AIDS-related primary central nervous system lymphoma with zidovudine, ganciclovir, and interleukin 2. *AIDS Res Hum Retroviruses* 1999;15:713-9.
65. Dworkin MS, Wan PC, Hanson DL, Jones JL. Progressive multifocal leukoencephalopathy: improved survival of human immunodeficiency virus-infected patients in the protease inhibitor era. *J Infect Dis* 1999;180:621-5.
66. Berger J, Gallo B, Concha M. Progressive Multifocal Leukoencephalopathy. In: Berger J, Levy R, eds. *AIDS and the Nervous System*. 2nd edition ed. Philadelphia: Lippincott-Raven, 1997:569-594.
67. Lafon ME, Dutronc H, Dubois V, Pellegrin I, Barbeau P, Ragnaud JM, Pellegrin JL, Fleury HJ. JC virus remains latent in peripheral blood B lymphocytes but replicates actively in urine from AIDS patients. *J Infect Dis* 1998;177:1502-5.
68. Berger JR, Major EO. Progressive multifocal leukoencephalopathy. *Semin Neurol* 1999;19:193-200.
69. Fong IW, Toma E. The natural history of progressive multifocal leukoencephalopathy in patients with AIDS. Canadian PML Study Group. *Clin Infect Dis* 1995;20:1305-10.
70. Miralles P, Berenguer J, Viedma Dd, Padilla B, et al. Treatment of AIDS-associated progressive multifocal leukoencephalopathy with highly active antiretroviral therapy. *AIDS* 1998;12:2467-72.
71. Moreno S, Miralles P, Diaz D, Berenguer J, et al. Cytarabine therapy for progressive multifocal leukoencephalopathy in patients with AIDS. *Clin Infect Dis* 1996;23:1066-68.
72. Berger JR, Pall L, Lanska D, Whiteman M. Progressive multifocal leukoencephalopathy in patients with HIV infection. *J Neurovirol* 1998;4:59-68.
73. Cinque P, Casari S, Bertelli D. Progressive multifocal leukoencephalopathy, HIV, and highly active antiretroviral therapy. *N Engl J Med* 1998;339:848-9.
74. Clifford D, Yiannoutsos C, Glicksman M, Simpson D, et al. HAART improves prognosis in HIV-associated progressive multifocal leukoencephalopathy. *Neurology* 1999;52:623-25.
75. Hall C, Dafni U, Simpson D, Clifford D, et al. Failure of cytarabine in progressive multifocal leukoencephalopathy associated with human immunodeficiency virus infection. *N Engl J Med* 1998;338:1345-51.
76. Karahalios D, Breit R, Canto MD, Levy R. Progressive multifocal leukoencephalopathy in patients with HIV infection: lack of impact of early diagnosis by stereotactic brain biopsy. *J Acquir Immune Defic Syndr* 1992;5:1030-38.
77. Albrecht H, Hoffmann C, Degen O, Stoehr A, Plettenberg A, Mertenskötter T, Eggers C, Stellbrink HJ. Highly active antiretroviral therapy significantly improves the prognosis of patients with HIV-associated progressive multifocal leukoencephalopathy. *AIDS* 1998;12:1149-54.



78. Gasnault J, Taoufik Y, Goujard C, Kousignian P, Abbed K, Boue F, Dussaix E, Delfraissy JF. Prolonged survival without neurological improvement in patients with AIDS-related progressive multifocal leukoencephalopathy on potent combined antiretroviral therapy. *J Neurovirol* 1999;5:421-9
79. De Girolami U, Anthony D, Frosch M. The Central Nervous System. In: Cotran R, Kumar V, Collins T, eds. *Robbins Pathologic Basis of Disease*. Sixth ed. Philadelphia: W.B. Saunders Co., 1999:1293-1357
80. Post MJ, Yiannoutsos C, Simpson D, Booss J, Clifford DB, Cohen B, McArthur JC, Hall CD. Progressive multifocal leukoencephalopathy in AIDS: are there any MR findings useful to patient management and predictive of patient survival? AIDS Clinical Trials Group, 243 Team. *AJNR Am J Neuroradiol* 1999;20:1896-906
81. de Luca A, Cingolani A, Linzalone A, Ammassari A, Murri R, Giancola ML, Maiuro G, Antinori A. Improved detection of JC virus DNA in cerebrospinal fluid for diagnosis of AIDS-related progressive multifocal leukoencephalopathy. *J Clin Microbiol* 1996;34:1343-6
82. Hammarin AL, Bogdanovic G, Svedhem V, Pirskanen R, Morfeldt L, Grandien M. Analysis of PCR as a tool for detection of JC virus DNA in cerebrospinal fluid for diagnosis of progressive multifocal leukoencephalopathy. *J Clin Microbiol* 1996;34:2929-32
83. Taoufik Y, Gasnault J, Karaterki A, Ferey M, et al. Prognostic value of JC virus load in cerebrospinal fluid of patients with progressive multifocal leukoencephalopathy. *J Infect Dis* 1998;178:1816-20
84. Yiannoutsos CT, Major EO, Curfman B, Jensen PN, Gravell M, Hou J, Clifford DB, Hall CD. Relation of JC virus DNA in the cerebrospinal fluid to survival in acquired immunodeficiency syndrome patients with biopsy-proven progressive multifocal leukoencephalopathy. *Ann Neurol* 1999;45:816-21
85. Giudici B, Vaz B, Bossolasco S, Casari S, Brambilla A, et al. Highly active antiretroviral therapy and progressive multifocal leukoencephalopathy: effects on cerebrospinal fluid markers of JC virus replication and immune response. *Clin Infect Dis* 2000;30:95-99
86. Garcia de Viedma D, Alonso R, Miralles P, Berenguer J, Rodriguez-Creixems M, Bouza E. Dual qualitative-quantitative nested PCR for detection of JC virus in cerebrospinal fluid: high potential for evaluation and monitoring of progressive multifocal leukoencephalopathy in AIDS patients receiving highly active antiretroviral therapy. *J Clin Microbiol* 1999;37:724-8
87. Berger JR, Levy RM, Flomenhoft D, Dobbs M. Predictive factors for prolonged survival in acquired immunodeficiency syndrome-associated progressive multifocal leukoencephalopathy. *Ann Neurol* 1998;44:341-9
88. Brambilla AM, Castagna A, Novati R, Cinque P, Terreni MR, Moioli MC, Lazzarin A. Remission of AIDS-associated progressive multifocal leukoencephalopathy after didanosine therapy. *J Neurol* 1999;246:723-5
89. Chocarro Martinez A, Gonzalez Lopez A, Garcia Garcia I. Successful resolution of progressive multifocal leukoencephalopathy after combination therapy with didanosine and cytosine arabinoside. *Clin Infect Dis* 2000;30:234
90. De Luca A, Fantoni M, Tartaglione T, Antinori A. Response to didanosine after failure of antiretroviral therapy alone in AIDS-associated progressive multifocal leukoencephalopathy. *Neurology* 1999;52:891-92
91. Sadler M, Morris-Jones S, Nelson M, Gazzard BG. Successful treatment of cytomegalovirus encephalitis in an AIDS patient using didanosine. *AIDS* 1997;11:1293-4
92. Gasnault J, Taoufik Y, Abbed K, Kousignian P, Goujard C, Dussaix E, Delfraissy JF. Experience of didanosine in HIV-associated progressive multifocal leukoencephalopathy: clinical and virological monitoring. In: Abstracts of the 6th Conference on Retroviruses and Opportunistic Infections. San Francisco, 1999
93. Elliot B, Aromin I, Gold R, Flanigan T, Mileno M. 2.5 year remission of AIDS-associated progressive multifocal leukoencephalopathy with combined antiretroviral therapy. *Lancet* 1997;349:850
94. Power C, Nath A, Aoki F, Bigio Md. Remission of progressive multifocal leukoencephalopathy following splenectomy and antiretroviral therapy in a patient with HIV infection. *N Engl J Med* 1997;336:661-62
95. Baqi M, Kucharczyk W, Walmsley SL. Regression of progressive multifocal encephalopathy with highly active antiretroviral therapy. *AIDS* 1997;11:1526-7
96. Baldeweg T, Catalan J. Remission of progressive multifocal leukoencephalopathy after antiretroviral therapy. *Lancet* 1997;349:1554-5
97. Domingo P, Guardiola JM, Iranzo A, Margall N. Remission of progressive multifocal leukoencephalopathy after antiretroviral therapy. *Lancet* 1997;349:1554-5

98. Inui K, Miyagawa H, Sashihara J, Miyoshi H, Tanaka-Taya K, Nishigaki T, Teraoka S, Mano T, Ono J, Okada S. Remission of progressive multifocal leukoencephalopathy following highly active antiretroviral therapy in a patient with HIV infection. *Brain Dev* 1999;21:416-9
99. Teofilo E, Gouveia J, Brotas V, da Costa P. Progressive multifocal leukoencephalopathy regression with highly active antiretroviral therapy. *AIDS* 1998;12:449
100. Tassie JM, Gagnault J, Bentata M, Deloumeaux J, Boue F, Billaud E, Costagliola D. Survival improvement of AIDS-related progressive multifocal leukoencephalopathy in the era of protease inhibitors. Clinical Epidemiology Group. French Hospital Database on HIV. *AIDS* 1999;13:1881-7
101. Tantisiriwat W, Tebas P, Clifford D, Powderly W, Fichtenbaum C. Progressive multifocal leukoencephalopathy in patients with AIDS receiving highly active antiretroviral therapy. *Clin Infect Dis* 1999;28
102. De Luca A, Ammassari A, Cingolani A, Giancola ML, Antinori A. Disease progression and poor survival of AIDS-associated progressive multifocal leukoencephalopathy despite highly active antiretroviral therapy. *AIDS* 1998;12:1937-8
103. Collazos J, Mayo J, Martinez E, Blanco M. Contrast-enhancing progressive multifocal leukoencephalopathy as an immune reconstitution event in AIDS patients. *AIDS* 1999;13:1426-28
104. Saillour F, Bernard N, et al. Predictive factors of occurrence of cytomegalovirus disease and impact on survival in the Aquitaine cohort in France, 1985 to 1994. *Journal of Acquired Immune Deficiency Syndrome* 1998;17:171-178
105. Studies of ocular complications of AIDS research group in collaboration with the AIDS clinical trial group. Foscarnet-Ganciclovir cytomegalovirus retinitis trial: 5. Clinical features of cytomegalovirus retinitis at diagnosis. *Am J Ophthalmol* 1997;124:141-157
106. Arribas JR, Storch GA, Clifford DB, Tselis AC. Cytomegalovirus encephalitis. *Ann Intern Med* 1996;125:577-587
107. Holland N, Power C, Mathews V, Glass J, Forman M, McArthur J. Cytomegalovirus encephalitis in acquired immunodeficiency syndrome (AIDS). *Neurology* 1994;44:507-14
108. Morgello S, Cho ES, Nielsen S, Devinsky O, Petito CK. Cytomegalovirus encephalitis in patients with acquired immunodeficiency syndrome: an autopsy study of 30 cases and a review of the literature. *Hum Pathol* 1987;18:289-97
109. Anduze-Faris BM, Fillet AM, Gozlan J, Lancar R, Boukli N, Gagnault J, Caumes E, Livartowsky J, Matheron S, Leport C, Salmon D, Costagliola D, Katlama C. Induction and maintenance therapy of cytomegalovirus central nervous system infection in HIV-infected patients. *AIDS* 2000;14:517-24
110. Kalayjian RC, Cohen ML, Bonomo RA, Flanagan TP. Cytomegalovirus ventriculoencephalitis in AIDS. *Medicine* 1993;72:67-77
111. McCutchan JA. Cytomegalovirus infections of the nervous system in patients with AIDS. *Clin Infect Dis* 1995;20:747-54
112. Gozlan J, Salord JM, Roulet E, Baudrimont M, Caburet F, Picard O, Meyohas MC, Duvivier C, Jacomet C, Petit JC. Rapid detection of cytomegalovirus DNA in cerebrospinal fluid of AIDS patients with neurologic disorders [published erratum appears in *J Infect Dis* 1993 Apr;167(4):995]. *J Infect Dis* 1992;166:1416-21
113. Wolf DG, Spector SA. Diagnosis of human cytomegalovirus central nervous system disease in AIDS patients by DNA amplification from cerebrospinal fluid. *J Infect Dis* 1992;166:1412-5
114. Revello M, Percivalle E, Sarasini A, Baldanti F, Furione M, Gerna G. Diagnosis of human cytomegalovirus infection of the nervous system by pp65 detection in polymorphonuclear leukocytes of cerebrospinal fluid from AIDS patients. *J Infect Dis* 1994;170:1275-9
115. Fox J, Brink NS, Zuckerman MA, et al. Detection of herpesvirus DNA by nested polymerase chain reaction in cerebrospinal fluid of human immunodeficiency virus-infected persons with neurologic disease: a prospective evaluation. *J Infect Dis* 1995;172:1087-90
116. Arribas JR, Clifford DB, Fichtenbaum CJ, et al. Level of cytomegalovirus (CMV) DNA in cerebrospinal fluid of subjects with AIDS and CMV infection of the central nervous system. *J Infect Dis* 1995;172:527-31
117. Cinque P, Baldanti F, Vago L, Terreni MR, et al. Ganciclovir therapy for cytomegalovirus (CMV) infection of the central nervous system in AIDS patients: monitoring by CMV DNA detection in cerebrospinal fluid. *J Infect Dis* 1995;171:1603-6
118. Grassi MP, Clerici F, Perin C, D'Arminio Monforte A, Vago L, Borella M, Boldorini R, Mangoni A. Microglial nodular encephalitis and ventriculoencephalitis due to cytomegalovirus infection in patients with AIDS: two distinct clinical patterns. *Clin Infect Dis* 1998;27:504-8

119. Shepp DH, Dandliker PS, de Miranda P, Burnette TC, Cederberg DM, Kirk LE, Meyers JD. Activity of 9-[2-hydroxy-1-(hydroxymethyl)ethoxymethyl]guanine in the treatment of cytomegalovirus pneumonia. *Ann Intern Med* 1985;103:368-73
120. Cohen BA. Prognosis and response to therapy of cytomegalovirus encephalitis and meningomyelitis in AIDS. *Neurology* 1996;46:444-50
121. Hengge U, Brockmeyer N, Malessa R, Ravens U, Goos M. Foscarnet penetrates the blood-brain barrier: rationale for therapy of cytomegalovirus encephalitis. *Antimicrob Agents Chemother* 1993;37:1010-14
122. Freitas VR, Fraser-Smith EB, Matthews TR. Increased efficacy of ganciclovir in combination with foscarnet against cytomegalovirus and herpes simplex virus type 2 in vitro and in vivo. *Antiviral Research* 1989;12:205-12
123. Manischewitz JF, Quinnan GV, Lane HC, Wittek AE. Synergistic effect of ganciclovir and foscarnet on cytomegalovirus replication in vitro. *Antimicrob Agents Chemother* 1990;34:373-75
124. Studies of Ocular Complications of AIDS Research Group in Collaboration with the AIDS Clinical Trials Group. Combination foscarnet and ganciclovir therapy vs monotherapy for the treatment of relapsed cytomegalovirus retinitis in patients with AIDS: The Cytomegalovirus Retreatment Trial. *Arch Ophthalmology* 1996;114:23-33
125. Karmochkine M, Molina J-M, Scieuc X, Welker Y, et al. Combined therapy with ganciclovir and foscarnet for cytomegalovirus polyradiculomyelitis in patients with AIDS. *Am J Med* 1994;97:196-7
126. Evaluation and management of intracranial mass lesions in AIDS: Report of the quality standards subcommittee of the American Academy of Neurology. *Neurology* 1998;50:21-26
127. Brannagan TH, 3rd. Retroviral-associated vasculitis of the nervous system. *Neurol Clin* 1997;15:927-44
128. Whiteman M, Post J, Sklar E. Neuroimaging of acquired immunodeficiency syndrome. In: Berger J, Levy R, eds. *AIDS and the Nervous System*. Second ed. Philadelphia: Lippincott-Raven Publishers, 1997:297-381
129. Post MD, Sheldon J, Hensley G, Soila K, et al. Central nervous system disease in acquired immunodeficiency syndrome: prospective correlation using CT, MR imaging, and pathologic studies. *Radiology* 1986;158:141-48
130. Ciricillo S, Rosenblum M. Use of Ct and MR imaging to distinguish intracranial lesions and to define the need for biopsy in AIDS patients. *J Neurosurg* 1990;73:720-24
131. Miller RF, Hall-Craggs MA, Costa DC, Brink NS, Scaravilli F, Lucas SB, Wilkinson ID, Ell PJ, Kendall BE, Harrison MJ. Magnetic resonance imaging, thallium-201 SPET scanning, and laboratory analyses for discrimination of cerebral lymphoma and toxoplasmosis in AIDS. *Sex Transm Infect* 1998;74:258-64
132. Hornef M, Iten A, Maeder P, Villemure J-G, Regli L. Brain biopsy in patients with acquired immunodeficiency syndrome. *Arch Intern Med* 1999;159:2590-6
133. Viswanathan R, Ironside J, Bell JE, Brettell RP, Whittle IR. Stereotactic brain biopsy in AIDS patients: does it contribute to patient management? *Br J Neurosurg* 1994;8:307-11
134. Antinori A, Ammassari A, Luzzati R, Castagna A, et al. Role of brain biopsy in the management of focal brain lesions in HIV-infected patients. *Neurology* 2000;54:993-7
135. Chappell E, Guthrie B, Orenstein J. The role of stereotactic biopsy in the management of HIV-related focal brain lesions. *Neurosurgery* 1992;30:825-9
136. Feiden W, Bise K, Steude U, Pfister H-W, Moller A. The stereotactic biopsy diagnosis of focal intracerebral lesions in AIDS patients. *Acta Neurol Scand* 1993;87:228-33
137. Iacoangeli M, Roselli R, Antinori A, Ammassari A, et al. Experience with brain biopsy in acquired immune deficiency syndrome-related focal lesions of the central nervous system. *Br J Surg* 1994;81:1508-11
138. Luzzati R, Ferrari S, Nicolato A, Piovan E, et al. Stereotactic brain biopsy in human immunodeficiency virus-infected patients. *Arch Intern Med* 1996;156:565-8
139. Monforte A, Clinique P, Vago L, Castagna A, et al. A comparison of brain biopsy and CSF-PCR in the diagnosis of CNS lesions in AIDS patients. *J Neurol* 1997;244:35-9
140. Zimmer C, Marzheuser S, Patt S, Rolfs A, et al. Stereotactic brain biopsy in AIDS. *J Neurol* 1992;239:394-400
141. Kaplan WD, Takvorian T, Morris JH, Rumbaugh CL, Connolly BT, Atkins HL. Thallium-201 brain tumor imaging: a comparative study with pathologic correlation. *J Nucl Med* 1987;28:47-52
142. Sehweil AM, McKillop JH, Milroy R, Wilson R, Abdel-Dayem HM, Omar YT. Mechanism of 201Tl uptake in tumours. *Eur J Nucl Med* 1989;15:376-9
143. Chin BB, Zukerberg BW, Buchpiguel C, Alavi A. Thallium-201 uptake in lung cancer. *J Nucl Med* 1995;36:1514-9

144. Brismar T, Collins VP, Kesselberg M. Thallium-201 uptake relates to membrane potential and potassium permeability in human glioma cells. *Brain Res* 1989;500:30-6
145. Antinori A, De Rossi G, Ammassari A, Cingolani A, Murri R, Di Giuda D, De Luca A, Pierconti F, Tartaglione T, Scerrati M, Larocca LM, Ortona L. Value of combined approach with thallium-201 single photon emission computed tomography and Epstein-Barr virus DNA polymerase chain reaction in CSF for the diagnosis of AIDS-related primary CNS lymphoma. *J Clin Oncol* 1999;17:554-560
146. D'Amico A, Messa C, Castagna A, Zito F, et al. Diagnostic accuracy and predictive value of <sup>201</sup>Tl SPET for the differential diagnosis of cerebral lesions in AIDS patients. *Nucl Med Commun* 1997;18:741-50
147. De La Pena RC, Ketonen L, Villanueva-Meyer J. Imaging of brain tumors in AIDS patients by means of dual-isotope thallium-201 and technetium-99m sestamibi single-photon emission tomography. *Eur J Nucl Med* 1998;25:1404-11
148. Gianotti N, Marenzi R, Messa C, Rosa Terreni M, Rocca A, Castagna A. Thallium-201 single photon emission computed tomography in the management of contrast-enhancing brain lesions in a patient with AIDS. *Clin Infect Dis* 1996;23:185-6
149. Lorberboym M, Estok L, Machac J, Germano I, et al. Rapid differential diagnosis of cerebral toxoplasmosis and primary central nervous system lymphoma by Thallium-201 SPECT. *J Nucl Med* 1996;37:1150-54
150. Lorberboym M, Wallach F, Estok L, Mosesson R, Sacher M, Kim C, Machac J. Thallium-201 retention in focal intracranial lesions for the differential diagnosis of primary lymphoma and nonmalignant lesions in AIDS patients. *Journal of Nuclear Medicine* 1998;39:1366-69
151. O'Malley J, Ziessman H, Kumar P, Harkness B, Tall J, Pierce P. Diagnosis of intracranial lymphoma in patients with AIDS: Value of 201-Tl single-photon emission computed tomography encephalitis in AIDS patients. *AJR* 1994;163:417-21
152. Ruiz A, Ganz W, Donovan-Post J, Camp A, Landy H, Mallin W, Sfakianakis G. Use of Thallium-201 Brain SPECT to differentiate cerebral lymphoma from toxoplasma encephalitis in AIDS patients. *Am J Neuroradiol* 1994;15:1885-94
153. Skiest D, Erdman W, Chang WE, Oz OK, Ware A, Fleckenstein J. SPECT Thallium-201 combined with *Toxoplasma* Serology for presumptive diagnosis of focal central nervous system mass lesions in patients with AIDS. *J Infection* 2000;40:274-81
154. Lee VW, Antonacci V, Tilak S, Fuller JD, Cooley TP. Intracranial mass lesions: sequential thallium and gallium scintigraphy in patients with AIDS. *Radiology* 1999;211:507-12
155. Iranzo A, Marti-Fabregas J, Domingo P, Catafau A, Molet J, Moreno A, Pujol J, Matias-Guiu X, Cadafalch J. Absence of thallium-201 brain uptake in progressive multifocal leukoencephalopathy in AIDS patients. *Acta Neurol Scand* 1999;100:102-5
156. Kessler LS, Ruiz A, Donovan Post MJ, Ganz WI, Brandon AH, Foss JN. Thallium-201 brain SPECT of lymphoma in AIDS patients: pitfalls and technique optimization. *AJNR Am J Neuroradiol* 1998;19:1105-9
157. Campbell B, Hurley J, Zimmerman R. False-negative single-photon emission CT in AIDS lymphoma: lack of effect of steroids. *AJNR* 1996;100:1000-1001
158. Fisher D, Chason D, Mathews D, Burns D, Fleckenstein J. Central nervous system lymphoma not detectable on single-photon emission CT with thallium 201. *AJNR* 1996;17:1687-90
159. Port JD, Miseljic S, Lee RR, Ali SZ, Nicol TL, Royal W, 3rd, Chin BB. Progressive multifocal leukoencephalopathy demonstrating contrast enhancement on MRI and uptake of thallium-201: a case report. *Neuroradiology* 1999;41:895-8
160. Hoffman J, Waskin H, Schifter T, Hanson M, Gray L, Rosenfeld S, Coleman R. FDG-PET in differentiating lymphoma from nonmalignant central nervous system lesions in patients in AIDS. *J Nucl Med* 1993;34:567-75
161. Menendez J, Lilien D, Nanda A, Polin R, et al. Use of fluorodeoxyglucose-positron emission tomography for the differentiation of cerebral lesions in patients with acquired immune deficiency syndrome. *Neurosurg Focus* 2000;8:1-8
162. Pierce M, Johnson M, Maciunas R, Murray M, Allen G, Harbison A, Creasy J, Kessler R. Evaluating contrast-enhancing brain lesions in patients with AIDS by using positron emission tomography. *Ann Intern Med* 1995;123:594-598
163. Heald AE, Hoffman JM, Bartlett JA, Waskin HA. Differentiation of central nervous system lesions in AIDS patients using positron emission tomography (PET). *Int J STD AIDS* 1996;7:337-46
164. O'Doherty MJ, Barrington SF, Campbell M, Lowe J, Bradbeer CS. PET scanning and the human immunodeficiency virus-positive patient. *J Nucl Med* 1997;38:1575-83

165. Villringer K, Jager H, Dichgans M, Ziegler S, Poppinger J, Herz M, Kruschke C, Minoshima S, Pfister HW, Schwaiger M. Differential diagnosis of CNS lesions in AIDS patients by FDG-PET. *J Comput Assist Tomogr* 1995;19:532-6
166. Rudkin T, Arnold D. Proton magnetic resonance spectroscopy for the diagnosis and management of cerebral disorders. *Arch Neurol* 1999;56:919-26
167. Chang L, Miller B, McBride D, Cornford M, Oropilla G, Buchthal S, Chiang F, Aronow H, Ernst T. Brain lesions in patients with AIDS: H-1 MR spectroscopy. *Radiology* 1995;197:525-31
168. Chinn R, Wilkinson I, Hall-Craggs M, Paley M, Miller R, Kendall B, Newman S, Harrison M. Toxoplasmosis and primary central nervous system lymphoma in HIV infection: Diagnosis with MR spectroscopy. *Radiology* 1995;197:649-54
169. Simone I, Federico F, Tortorella C, Andreola C, et al. Localised H-MR spectroscopy for metabolic characterisation of diffuse and focal brain lesions in patients infected with HIV. *J Neurol Neurosurg Psychiatry* 1998;64:516-23
170. Chang L, Ernst T, Tornatore C, Aronow H, et al. Metabolite abnormalities in progressive multifocal leukoencephalopathy by proton magnetic resonance spectroscopy. *Neurology* 1997;48:836-45
171. Iranzo A, Moreno A, Pujol J, Marti-Fabregas J, Domingo P, Molet J, Ris J, Cadafalch J. Proton magnetic resonance spectroscopy pattern of progressive multifocal leukoencephalopathy in AIDS. *J Neurol Neurosurg Psychiatry* 1999;66:520-3
172. Chong W, Sweeney B, Wilkinson I, Paley M, et al. Proton spectroscopy of the brain in HIV infection: correlation with clinical, immunologic, and MR imaging findings. *Radiology* 1993;188:119-24
173. Roberts TC, Storch GA. Multiplex PCR for diagnosis of AIDS-related central nervous system lymphoma and toxoplasmosis. *J Clin Microbiol* 1997;35:268-9