MEDICAL GRAND ROUNDS

PARKLAND MEMORIAL HOSPITAL

29 January 1976

PRIMARY AMENORRHEA

For the purposes of this discussion, the definition of primary amenorrhea has been adapted from Speroff, Glass, and Kase (1):

1.) No period by age 16 in the absence of growth or development of secondary sex characteristics

2.) No period by age 18 regardless of the presence of normal growth and development and the appearance of secondary sexual characteristics.

1. Speroff, L., R. H. Glass, and N. A. Kase. Clinical Gynecologic Endocrinology and Infertility. The Williams and Wilkins Co., Baltimore, 1973.

In the recent past we have devoted three grand rounds to specific causes of primary amenorrhea - testicular feminization, other causes of hereditary male pseudohermaphroditism and gonadal dysgenesis. What we propose to undertake in this discussion is to focus attention on a third specific cause of primary amenorrhea, congenital absence of the vagina, and to conclude with a discussion of the differential diagnosis and workup for the disorders that result in primary amenorrhea. The reason for focusing on one specific problem is twofold. First, although in published series the disorder is the second most common cause of primary amenorrhea, and although the disorder is well known to gynecologists, it has been largely ignored in the medical literature. Indeed it is not even mentioned in some reference texts on abnormal sexual development. Second, we have recently summarized the combined experience in 14 patients with the disorder that have been seen by the Ob-Gyn and Medical services of this hospital in the past few years, and as a result we have become interested in the pathogenesis of the disorder (2). I might add that this effort has been a cooperative one of many people. Several physicians - Stanley Feld, Norman Gant, Michael de Larios, and William Midgett - allowed us to study their patients. Three postdoctoral fellows - Regula Schweikert, Guido Verhoeven, and Gunther Jacobi - translated the key foreign language references. Dr. Mary Jo Harrod worked up the family pedigrees, Dr. R. Santos-Romas performed the ultrasonographic studies that will be described, James Madden and Creighton Edwards directed the gynecological workup and treatment of most of the patients, and James Griffin assembled all the clinical data on these patients and reviewed the literature.

2. Griffin, J. E., C. Edwards, J. D. Madden, M. J. Harrod, and J. D. Wilson. Congenital Absence of the Vagina. The Mayer-Rokitansky-Kuster-Hauser Syndrome. Report of 14 Cases and a Review of the Literature. Submitted for Publication.

Congenital Absence of the Vagina

The recognition that the combination of congenital absence of the vagina associated with some form of abnormal or absent uterus constitutes a syndrome is principally the work of four individuals. Mayer described congenital absence of the vagina in 1839 as one abnormality in stillborn infants with

multiple birth defects (3). Subsequently, Rokitansky in 1838 (4) and Kuster in 1910 (5) delineated an entity in which the vagina is absent, a rudimentary, bipartite uterus is present, the ovaries are usually normal (Fig. 1), and renal and skeletal anomalies are common. Hauser and his colleagues subsequently emphasized the frequency of the disorder and the spectrum of associated abnormalities (6-9). Pinsky suggested that congenital absence of the vagina is a part of a symptom complex rather than a true syndrome (10), but it seems appropriate to refer to the disorder as the Mayer-Rokitansky-Kuster-Hauser syndrome, although it has also been termed the Rokitansky-Kuster-Hauser syndrome (11).

3. Mayer: Ueber verdoppelungen des uterus und ihre arten, nebst bemerkungen über hasenscharte und wolfsrachen. J. Chir. Auger. 13:525-564, 1829.

4. Rokitansky: Über die sogenannten verdoppelungen des uterus. Med Jb. Öst. Staat. 26:39-77, 1838.

5. Kuster, H.: Uterus bipartitus solidus rudimentarius cum vagina solida. Zeitschr. f. Geb. u. Gyn. 67:692-718, 1910.

6. Hauser, G. A., Keller, M., Koller, Th. et al.: Das Rokitansky-Küster-syndrom. Uterus bipartitus solidus rudimentarius cum vagina solida. Gynaecologia 151:111-112, 1961.

7. Hauser, G. A. and Schreiner, W. E.: Das Mayer-Rokitansky-Küster-syndrom. Schweiz. med. Wschr. 91:381-384, 1961.

8. Schmid-Tannwald, I., Girotti, M. and Hauser, G. A.: Die formalgenese weiblicher, innerer genitalaplasien, speziell des Mayer-Rokitansky-Küster-syndroms. Zbl. Gynäk. 95:421-428, 1973.

9. Schmid-Tannwald, I. and Hauser, G. A.: Gegenüberstellung von testikulärer feminisierung und Mayer-Rokitansky-Küster-syndrom. Geburtsh, u. Frauenheilk. 33:194-198, 1973.

10. Pinsky, L.: A community of human malformation syndromes involving the Mullerian ducts, distal extremities, urinary tract, and ears. Teratology 9:65-79, 1974.

11. Golditch, I. M.: Vaginal aplasia. Surg. Gyn. Obst. 129:361-367, 1969.

The literature on the subject is extensive, at least 17 series involving some 500 cases having been reported since 1948, but most papers in English have focused on the management of the gynecological abnormalities.

Incidence

The frequency of congenital absence of the vagina is not entirely clear, incidences having been reported as varying from 1 in 4-5000 female births (12, 13) to 1 in 20,000 female hospital admissions (14). If considered from the standpoint only of women presenting with primary amenorrhea, the diagnosis in this group of patients is fairly common. Indeed in one series the disorder

ranked second to gonadal dysgenesis as a cause of primary amenorrhea (15), and in another it was third in frequency after gonadal dysgenesis and hypogonadotrophic hypogonadism (16). In the series reported by Fore, Hammond, Parker et al the disorder was about 10 times as frequent as testicular feminization (17), but it is considerably less frequent than the associated anomalies such as congenital absence and ectopia of the kidney (18-22) and abnormalities of the vertebrae (23).

12. Engstad, J. E.: Artificial vagina. J. Lancet 37:329-331, 1917.

13. Bryan, A. L., Nigro, J. A. and Counseller, V. S.: One hundred cases of congenital absence of the vagina. Surg. Gyn. Ob. 88:79-86, 1949.

14. Owens, N.: Simplified method for formation of an artificial vagina by split skin graft. Report of a case. Surg. 12:139-150, 1942.

15. Grover, S., Solanki, B. R. and Banerjee, M.: A clinicopathologic study of Müllerian duct aplasia with specific reference to cytogenetic studies. Am. J. Ob. Gyn. 107:133-138, 1970.

16. Reschini, E., Giustina, G., D'Alberton, A. et al.: Radioimmunoassayable plasma luteinizing hormone in primary amenorrhea. Am. J. Ob. Gyn. 111:173-177, 1971.

17. Fore, S. R., Hammond, C. B., Parker, R. T. et al.: Urologic and genital anomalies in patients with congenital absence of the vagina. Ob. Gyn. 46:410-416, 1975.

18. Hennessey, R. A.: Congenital solitary kidney. J. Urol. 21:193-204, 1929.

19. Collins, D. C.: Congenital unilateral renal agenesia. Ann. Surg. 95:715-726, 1932.

20. Carpentier, P. J. and Potter, E. L.: Nuclear sex and genital malformation in 48 cases of renal agenesis, with especial reference to nonspecific female pseudohermaphroditism. Am. J. Ob. Gyn. 78: 235-258, 1959.

21. Felding, C.: Obstetric studies in women with congenital solitary kidneys. Acta obst. et gynec. scandinav. 44:555-562, 1965.

22. Vitko, R. J., Cass, A. S. and Winter, R. B.: Anomalies of the genitourinary tract associated with congenital scoliosis and congenital kyphosis. J. Urol. 108:655-659, 1972.

23. Blumel, J., Evans, E. B., Hadnott, J. L. et al.: Congenital skeletal anomalies of the spine: An analysis of the charts and roentgenograms of 264 patients. Amer. Surg. 28:501-509, 1962.

Clinical Features of the Syndrome

The principal clinical features of the Mayer-Rokitansky Kuster-Hauser syndrome are summarized in Table I. Most patients are identified after the time of expected menarche because of primary amenorrhea and are found on physical examination to have absence of the vagina. The uterus may vary from a virtually normal state, lacking only a conduit to the introitus, to the more characteristic finding of rudimentary bicornuate cords with or without a lumen. The typical anatomical findings are illustrated in Figure I, a reproduction of the operative findings in the index case described by Rokitansky (4).

The karyotype is that of a normal 46,XX woman, and ovarian function is normal both in regard to ovulation and endocrine function; e.g. biphasic basal body temperature patterns are usual, and body development at the time of expected puberty is normal in that breast enlargement and the growth of axillary and pubic hair occur on schedule. Cyclic abdominal pain is prominent in those patients in whom a partial endometrial cavity is present. There is a frequent occurrence of renal, skeletal, and other congenital anomalies in affected patients.

Table I

PRINCIPAL CLINICAL FEATURES OF THE

MAYER-ROKITANSKY-KUSTER-HAUSER SYNDROME

1. PRIMARY AMENORRHEA ASSOCIATED WITH CONGENITAL ABSENCE OF THE VAGINA
2. 46,XX KARYOTYPE
3. UTERUS THAT VARIES FROM ANATOMICALLY COMPLETE TO RUDIMENTARY BICORNUATE CORDS TO COMPLETE ABSENCE
4. NORMAL OVARIAN FUNCTION AND NORMAL OVULATION
5. NORMAL FEMALE BREAST DEVELOPMENT, BODY PROPORTIONS, AND BODY HAIR
6. FREQUENT ASSOCIATION OF RENAL, SKELETAL, AND OTHER CONGENITAL ANOMALIES

FIGURE 1. ANATOMIC FINDINGS IN THE PROPOSITUS CASE DESCRIBED BY ROKITANSKY (4). THE FEATURES IN THE TUBES AND OVARIES AND THE ABSENCE OF THE VAGINA AND UTERUS ARE TYPICAL.

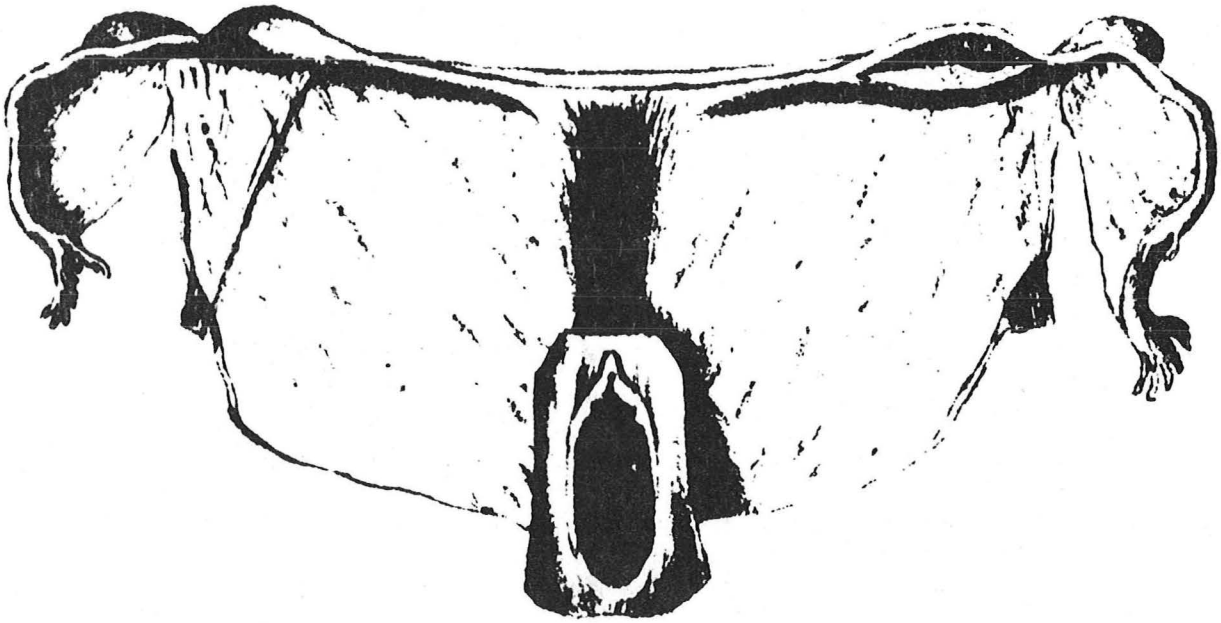

Table 2 Clinical Features in 14 Patients With Congenital Absence of the Vagina

Case	Age: Dx	Age: Examination	History: Sexual Pain	History: Family History	Height cm	Findings: Pelvic Examination (Initial)	Findings: Laparoscopy Laparotomy for Dx	Karyotype	Skeletal Abnormalities	Urinary Tract Abnormalities	Other	Treatment (Pt. Result): Medical	Treatment (Pt. Result): Surgical
1.) NB -	16	24	None	Negative	168	Blind-ending vagina*	None	46XX	None	None	Sonography-? X 3 cm mass in region of uterus	Age 21; adequate intercourse with 4 cm vagina	
2.) LA -	10	22	None	Affected sister (Case 3)	170	Blind-ending vagina*	Laparoscopy age 21; no uterus seen	46XX (Tandem satellites #14)	Mild lumbar scoliosis	Ptosis of right kidney	None	Age 14; adequate intercourse with 8 cm vagina	
3.) IT -	12	38	Yes	Affected sister (Case 2)		Blind-ending vagina*	Bipartite uterus removed age 20		None	Hydronephrosis left			Age 20; 2 surgical reconstructions with adequate intercourse now
4.) AC -	15	16	Yes	Mother with scoliosis		Vagina represented by dimple only	None	46XX	None	None	Sonography - no uterus detected	Age 16; course of treatment incomplete	
5.) ND -	16	27	None	Negative	154	Blind-ending 3 cm vagina	Age 19 "nubbin" of uterus removed	46XX Prominent short arm #15	Severe thoraco-lumbar scoliosis & failure of segmentation; Klippel-Feil deformity; short left 5th metacarpal	None	Deafness in left ear Bilateral salpingo-oophorectomy for "ovarian cysts"		Age 23; with good functional result
6.) JS -	13	23	None	Negative	157	Blind-ending 1 cm vagina; atrophied right labia majora & minora	No uterus remnant on laparotomy	46XX	Severe thoraco-lumbar scoliosis & spina bifida occulta	Deformity one upper pole calyx on left		Age 20; satisfactory intercourse	
7.) CH -	15	16	Yes	Negative		Blind-ending 3 cm vagina	Small uterus attached to artificial vagina	46XX	None	Small right kidney	Cleft lip, esotropia, multiple cortic coarctations		Age 16; with repeat due to fistula now satisfactory with connection to uterus
8.) DS -	16	17	Yes	Negative	159	Blind-ending vagina*	None	46XX (D chromosome had prominent short arm)	Sacralization L5 with transitional vertebrae	Congenital absence right kidney	Tetralogy of Fallot repaired age 7	Age 17; course of treatment incomplete	
9.) MC -	18	37	None	Negative	159	Blind-ending vagina*	None	46XX	Not examined	No IVP			Age 24; with 3 cm depth now)
10. RV -	17	25	None	Negative	154	No vaginal opening and some labia minora fusion	None	46XX	Lumbarization of S1 vertebra, mild scoliosis	Ectopic left kidney with sacral location	Left thenar eminence loss	Age 21; 10 cm now	
11. AF -	18	27	None	Negative	147	4 cm blind-ending vagina	None	46XX	mild scoliosis at L2-L3 failure of segmentation of C3 & C4, thoracic scoliosis; Klippel-Feil deformity	None		Age 24; now 10 cm	
12. SB -	17	18	Yes	Negative	157	Vagina represented by dimple only	None	46XX	None	None	Systolic murmur, et?	Age 18; satisfactory result	
13. PJ -	15	15	None	Negative	157	Blind-ending 1 cm vagina	None	46XX	None	Congenital absence left kidney	None	Age 15; course of treatment complete	
14. TW -	17	18	None	Sister with scoliosis; maternal aunt with bicornuate uterus.	159	Blind-ending 4 cm vagina	None	46XX	Severe thoraco-lumbar scoliosis	Congenital absence left kidney	None	Age 8; course of treatment incomplete	

*Patient not seen by us until after commencement of therapy; initial length of vagina not documented

The spectrum of the genital and nongenital findings in 14 patients studied here is illustrated in Table 2. The average age at the time of diagnosis was 16 and varied from 10 in one patient whose older sister was affected to 18 years. Five of the patients gave a history of cyclic abdominal pain. Two patients gave an initial history of family involvement.

FIGURE 2. FAMILY PEDIGREES FOR THREE PATIENTS STUDIED HERE (CASES 1 AND 2, FAMILY 1 and CASE 14, FAMILY 2)

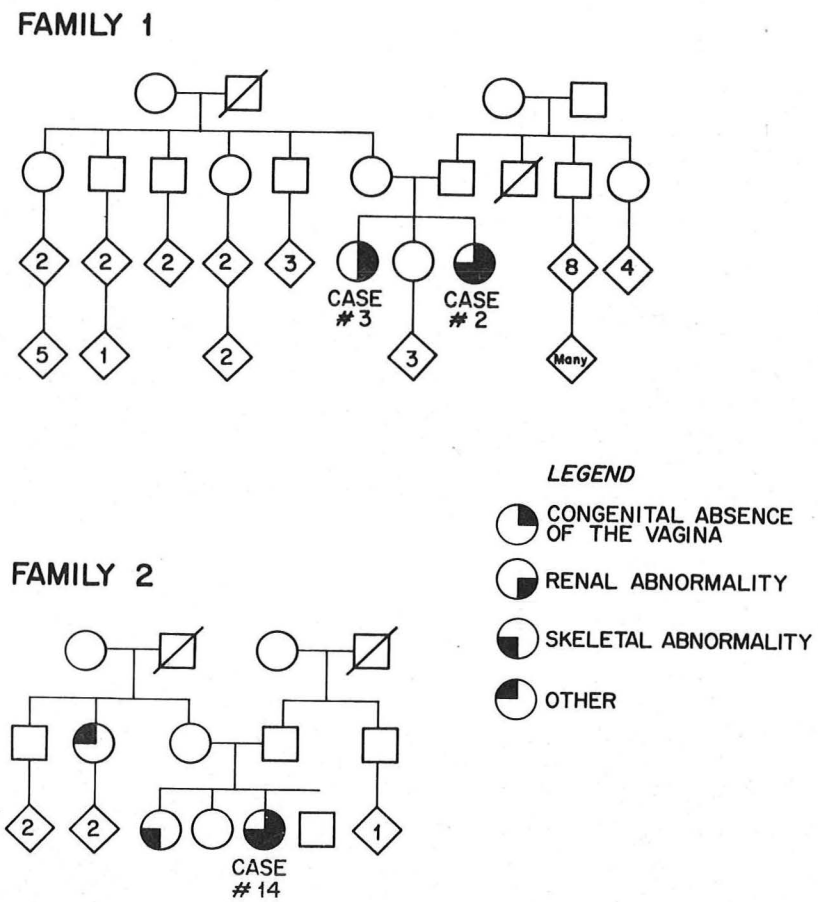

Patient 2 (LA) had an affected sister who had been diagnosed elsewhere and who was subsequently examined by us (Patient 3, IT). Patient 14 (TW), who also had severe thoracolumbar scoliosis, had a sister with scoliosis but normal cyclic menstrual periods and a maternal aunt with a double uterus. The mother of a third patient (Case 4, AC) has severe scoliosis. In the remaining 10 patients the family history was negative. The birth order of the patients was uninformative.

The physical findings were of interest. The average height was that of normal women, and breast development, axillary hair, and pubic hair were female in character. The introitus was normal, and in all but two the clitoris, labia majora, and labia minora were symmetrical and normal. In one (Case 6, JS) the labia majora was underdeveloped on one side, and in Case 10 (RV) there was minimal fusion of the labia minora. The vagina was completely absent (dimple only) in four cases, and in the remainder it constituted a blind-ending pouch that varied from 1-6 cm in depth. Laparoscopy and/or laparotomy was performed in 5 patients. In one (Case 6, JS) no uterine remnant was found, in three a bipartite uterine remnant was present, and in the fifth (Case 7, CH) a uterus with hematometra was present. In all five the ovaries were considered normal, but in one patient a "cystic ovary" had been removed previously. In Case 7 one tube and one ovary were removed because of extensive endometriosis.

The frequency of extragenital anomalies in this group of 14 patients is of considerable interest. Eight of the patients had urinary tract abnormalities identified by intravenous pyelography. This is more frequent than the over-all incidence of 34% in 520 patients described in 17 series in the literature (Table 3)(7, 13, 15, 17, 24-40). The incidence of skeletal abnormalities in the present series (7/14) is also greater than that in the same published series (64/560 cases) summarized in Table 3; these differences are probably due to the fact that excretory urograms and skeletal surveys were obtained in most of our patients, whereas it is not clear whether such studies were performed routinely in most reports.

Severe cardiac abnormalities were present in two individuals - tetralogy of Fallot in Case 8 (DS) and coarctation of the aorta in Case 7 (CH), who also had a cleft lip and esotropia. Two patients, Case 5 (ND) and Case 11 (AF), had the Klippel-Feil abnormality. Deafness in one ear was present in one, and Case 10 exhibited underdevelopment of the left thenar eminence. Since certain of the extragenital anomalies are a prominent feature of this syndrome, they will be considered in greater detail.

Table 3

Incidence of Non-Genital Abnormalities in Patients With Congenital Absence of the Vagina

Series #	Authors	Urinary tract abnormalities	Skeletal abnormalities	Congenital heart disease	Inguinal hernia	Other abnormalities
1	Counseller 1948 (24); Bryan, Nigro, & Counseller 1949 (13); Phelan, Counseller, & Greene 1953 (25); Cali & Pratt 1968 (26)	49/121	6/100		10/100	
2	Turunen 1957 (27) & Turunen & Unnerus 1967 (28)	21/73	25/200			
3	Barrows 1957 (29)	5/19	2/19			
4	Thompson, Wharton & TeLinde 1957 (30)	8/17				
5	Miller & Stout 1957 (31)	9/71	3/71	1/71	1/71	
6	Jones 1958 (32) & Jones & Scott (33)	4/11	1/11			
7	Hauser & Schreiner 1961 (7)	3/21	2/21	1/21	4/21	1 incompletely turned mesocolon
8	Chawla, Bery, & Indra 1966 (34)	11/23	4/23			
9	Azoury & Jones 1966 (35)	3/12	1/12	1/12	1/12	1 deafness, unilateral
10	Stabler 1966 (36)	12/19				
11	Leduc, Van Campenhout, & Simard 1968 (37)	5/12	4/12		1/12	1 situs inversus
12	Barclay 1968 (in discussion of Cali & Pratt (26)	10/17	4/17	1/17		
13	Papp, Gardo, Herpay, et al. 1970 (38)	7/14	4/14			
14	Grover, Solarki, & Banerjee 1970 (15)	3/15		1/18		
15	Wabrek, Millard, Wilson, et al. 1971 (39)	3/7	1/10			
16	Ortiz-Monasterio et al. 1972 (40)	2/32	4/32	1/32		1 atrophy of thenar eminence
17	Fore et al. 1975 (17)	17/36	3/18	1/39		
18	Present series	8/14	7/14	3/14	0/14	1 atrophy of thenar eminence; 1 deafness
	TOTAL	180/534 (34%)	71/574 (12%)	10/224 (4%)	17/230 (7%)	

24. Counseller, V. S.: Congenital absence of the vagina. J. Am. Med. Assoc. 136:861-866, 1948.

25. Phelan, J. T., Counseller, V. S. and Greene, L. R.: Deformities of the urinary tract with congenital absence of the vagina. Surg. Gyn. Obs. 97:1-3, 1953.

26. Cali, R. W. and Pratt, J. H.: Congenital absence of the vagina. Am. J. Ob. Gyn. 100:752-763, 1968.

27. Turunen, A.: Über kongenitales fehlen der scheide. Ann. Chir. Gyn. Fin. 46:125-142, 1957.

28. Turunen, A. and Unnérus, C.-E.: Spinal changes in patients with congenital aplasia of the vagina. Acta obst. et gynec. scandinav. 46:99-106, 1967.

29. Barrows, D. N.: Results after construction of artificial vaginas. Am. J. Ob. Gyn. 73:609-614, 1957.

30. Thompson, J. D., Wharton, L. R. and Te Linde, R. W.: Congenital absence of the vagina. An analysis of thirty-two cases corrected by the McIndoe operation. Am. J. Ob. Gyn. 74:397-404, 1957.

31. Miller, N. F. and Stout, W.: Congenital absence of the vagina. Ob. Gyn. 9:48-54, 1957.

32. Jones, H. W., Jr.: Operations for congenital anomalies of the uterus and vagina. Clin. Obst. Gyn. 2:1053-1066, 1959.

33. Jones, H. W. Jr. and Scott, W. W.: Hermaphroditism, Genital Anomalies and Related Endocrine Disorders. Baltimore, The Williams and Wilkins Co., 1958, p. 327.

34. Chawla, S., Bery, K. and Indra, K. J.: Abnormalities of urinary tract and skeleton associated with congenital absence of vagina. Br. Med. J. 1:1398-1400, 1966.

35. Azoury, R. S. and Jones, H. W., Jr.: Cytogenetic findings in patients with congenital absence of the vagina. Am. J. Ob. Gyn. 94:178-180, 1966.

36. Stabler, F.: Vaginal agenesis: Operative technique and the shape of the mould. J. Ob. Gyn. Brit. Cwlth. 73:463, 1966.

37. Leduc, B., Van Campenhout, J. and Simard, R.: Congenital absence of the vagina. Am. J. Ob. Gyn. 100:512-520, 1968.

38. Papp, Z., Gardo, S., Herpay, G. et al.: Developmental anomalies of the Müllerian ducts. Schweiz. Z. Gynak. Geburtsh. 1:115-121, 1970.

39. Wabrek, A. J., Millard, P. R., Wilson, W. B. Jr. et al.: Creation of a neovagina by the Frank nonoperative method. Ob. Gyn. 37:408-413, 1971.

40. Ortiz-Monasterio, F., Serrano, A., Barrera, G. et al.: Congenital absence of the vagina. Long-term follow-up in 21 patients treated with skin grafts. Plastic and Reconstructive Surg. 49:165-170, 1972.

Extragenital Anomalies

Renal Abnormalities: The association between congenital absence of the vagina and developmental abnormalities of the urogenital system was recognized very early (4, 5), and approximately one third of 534 patients from 18 case series (Table 3) have abnormal kidneys as delineated by intravenous pyelograms. A detailed breakdown of the type of kidney abnormalities identified in these patients is given in Table 4.

Table 4

CLASSIFICATION OF 164 UROLOGIC ABNORMALITIES

IN 162 PATIENTS WITH RENAL INVOLVEMENT*

		No.	%
1)	ECTOPIC KIDNEY	71	43
	WITH OTHER KIDNEY NORMAL	49	30
	WITH OTHER KIDNEY ABSENT	20	12
	WITH OTHER KIDNEY ECTOPIC	2	1
2)	AGENESIS OF KIDNEY	70	43
	WITH OTHER KIDNEY IN NORMAL POSITION	50	31
	WITH OTHER KIDNEY ECTOPIC	20	12
3)	ABNORMALITIES OF THE RENAL PELVIS AND/OR URETERS	19	12
4)	SOLITARY FUSED KIDNEY	8	5
5)	MALFUNCTIONING OR ATROPHIC KIDNEYS	8	5
6)	MALROTATION	7	4
7)	PRIOR NEPHRECTOMY (UNKNOWN REASON)	1	1

* Some patients had more than one abnormality

Seventy-four per cent of the patients had either agenesis of one kidney or ectopia of one or both kidneys; another 5% had solitary fused kidneys of the horseshoe type. The remaining defects included abnormalities of the collecting system (13%), malfunctioning kidneys of uncertain etiology (5%) or malrotation (5%). In addition to these reports there have been a number of case reports of the association of congenital absence of the vagina with solitary ectopic kidneys located in the pelvis (17, 41-48).

It is of interest that both cases in one family in the present series (Figure 2A) had kidney involvement. The functional significance of the kidney abnormalities is uncertain, although as would be expected many instances of pyelonephritis have been noted in the structurally abnormal kidneys (20), including one patient in the present series. The fact that the occurrence of renal agenesis and ectopic kidneys is common in this disorder means that special care should be taken to evaluate the kidneys prior to any operative procedures in the pelvis.

41. Barrows, D. N.: Kirschner-Wagner operation for construction of artificial vagina. Am. J. Ob. Gyn. 31:156-158, 1936.

42. Nalle, B. C. Jr., Crowell, J. A. and Lynch, K. M. Jr.: Solitary pelvic kidney with vaginal aplasia: Report of a case. J. Urol. 61:862-865, 1949.

43. Horn, P.: Surgical construction of an artificial vagina. Ann. West. Med. Surg. 4:591-598, 1950.

44. Keitzer, W. A. and Riemenschneider, E. A.: Congenital absence of the vagina with accompanying solitary pelvic kidney. Case report. J. Am. Med. Assoc. 142:987-988, 1950.

45. Verschoof, K. J. H. A rare congenital anomaly of the urogenital system. (Some embryological considerations). Gynaecologia 147: 164-171, 1959.

46. Crosby, W. M. and Hill, E. C.: Embryology of the Müllerian duct system. Review of present-day theory. Obs. Gyn. 20:507-515, 1962.

47. Tabrisky, J. and Bhisitkul, I.: Solitary crossed ectopic kidney with vaginal aplasia: A case report. J. Urol. 94:33-35, 1965.

48. Counseller, V. S. and Davis, C. E.: Atresia of the vagina. Ob. Gyn. 32:528-536, 1968.

Skeletal Abnormalities: Associated skeletal abnormalities were also recognized in the initial descriptions of the disease (4, 5). The overall incidence of skeletal abnormalities in 574 cases was 12% (Table 3), and the breakdown of these abnormalities is summarized in Table 5.

Table 5

CLASSIFICATION OF 70 SKELETAL ABNORMALITIES

IN 46 PATIENTS WITH SKELETAL INVOLVEMENT

	No.	%
1. SPINAL ABNORMALITIES	48	68
SCOLIOSIS (MILD TO SEVERE)	12	17
SPINA BIFIDA	9	13
SACRALIZATION OF L5 OR LUMBARIZATION S1	8	11
FAILURE OF SEGMENTATION OF VERTEBRAE (OTHER THAN L5 OR S1)	5	7
HEMIVERTEBRAE	2	3
KLIPPEL-FEIL DEFORMITY	3	4
"BUTTERFLY" VERTEBRAE	1	1
UNDEFINED SPINE ABNORMALITIES	8	11
2. LIMB ABNORMALITIES	10	14
MALFORMED ARM OR LEG	6	9
SYNDACTYLY	3	4
HIP DISLOCATION	1	1
3. OTHER ABNORMALITIES	12	17
RIB DEFORMITY OR EXTRA RIBS	7	10
SPRENGEL'S DEFORMITY OF SCAPULA	1	1
CLEFT PALATE	1	1
TORTICOLLIS	1	1
ASYNCLITISM OF PELVIS	1	1
PECTUS EXCAVATUM	1	1

* Some patients had more than one abnormality.

Of the various types of skeletal involvement, over two-thirds involve the spine, and limb and rib abnormalities account for the majority of the remaining defects. Both the frequency and severity of the spinal abnormalities have been emphasized by Turunen and Unnerus who identified 25 such cases in a series of some 200 cases of congenital aplasia of the vagina (28). The specific abnormalities included wedge vertebrae, fusions, rudimentary vertebral bodies and other asymmetry, and supernumerary vertebrae (28). These spinal abnormalities are similar in type and in distribution to those reported in the population at large (23).

Although the frequency of the Klippel-Feil abnormalities in the case series summarized in Tables 3 and 5 was low (3 in 46 patients with skeletal involvement) there are a number of individual reports in the literature of the association of congenital absence of the vagina with the Klippel-Feil syndrome (congenital fusion of the cervical spine, short neck, low posterior hairline, and painless limitation of cervical movement (37, 49-52), and two of the cases in the present series have this abnormality. There is also a known association between the Klippel-Feil abnormality and malformations of the kidney (37, 50, 52), but the frequency of absent vagina and/or renal abnormalities in large series of patients with Klippel-Feil is uncertain (53). However, Klippel-Feil has been documented to be transmitted as a single gene defect with variable manifestation in some families (53).

The association between defects of the urogenital system and other congenital abnormalities of the spine is well recognized (22). It is of interest, however, that some individuals in the present series had involvement of vagina and kidney without involvement of the spine and that others had involvement of spine and vagina with normal kidneys. Two individuals with involvement of spine and vagina (Cases 14 and 4) had family members with spinal abnormalities but normal vagina and uterus. These associations suggest the possibility that involvement of the spine, urogenital tract, and vagina may be variable manifestations of a common defect. Embryological considerations make this possibility even more likely (see below).

49. Park, I. J., Jones, H. W., Jr., et al.: A new syndrome in two unrelated females: Klippel-Feil deformity, conductive deafness and absent vagina, in Birth Defects. Part X: Original Article Series. Vol. VII, No. 6, ed. by Bergsma, D., Baltimore, Williams and Wilkins Co., 1971, p. 311.

50. Ramsey, J. and Bliznak, J.: Klippel-Feil syndrome with renal agenesis and other anomalies. Am. J. Roentg. Rad. Ther. Nucl. Med. 113:460-463, 1971.

51. Baird, P. A. and Lowry, R. B.: Absent vagina and the Klippel-Feil anomaly. Am. J. Ob. Gyn. 118:290-291, 1974.

52. Mecklenburg, R. S. and Krueger, P. M.: Extensive genitourinary anomalies associated with Klippel-Feil syndrome. Am. J. Dis. Child. 128:92-93, 1974.

53. Gunderson, C. H., Greenspan, R. H., Glaser, G. H. et al.: The Klippel-Feil syndrome: Genetic and clinical reevaluation of cervical fusion. Medicine 46:491-512, 1967.

Other Abnormalities: A variety of abnormalities of the hand have been described, including syndactyly (27), absence of a digit (54), and hypoplasia of the thenar eminence (40). Although inguinal and femoral hernias have been described, some of which contain ovaries, fallopian tubes, and the uterine remnants (55-58), the frequency of hernias is less in this disorder than in the testicular feminization syndrome (9).

Associated congenital heart lesions have also been described (7, 15, 26, 31, 35, 40) and were found in two of the present 14 cases, but it is not clear that such involvement is specific or that it is any more frequent than in association with other congenital birth defects. In contrast to certain other syndromes involving the urinary tract, deafness has been recorded only in rare instances (35, 49, 59) including one case in the present series (Table 2). A variety of other abnormalities have also been observed rarely such as cleft palate (29), situs inversus (37), and malrotation of the bowel (7)(Table 3).

54. Bruck, H. G., Kubista, E. and Wagenbichler, P.: Ein fall von Mayer-Rokitansky-Kuester-syndrom, kombiniert mit extragenitalen missbildungen. Geburtsh, u. Frauenheilk. 33:999-1003, 1973.

55. Deutschman, D.: Complete congenital absence of the vagina, associated with bilateral hernias of uterus, tubes and ovaries. N. Y. Med. J. and Med. Rec. 118:570-571, 1923.

56. Thomson, G. R.: Complete congenital absence of the vagina associated with bilateral herniae of uterus, tubes, and ovaries. Br. J. Surg. 36:99-100, 1948.

57. Whitely, J. M., Parrott, M. H. and Rowland, W.: Split-thickness skin graft technique in the correction of congenital or acquired vaginal atresia. Am. J. Ob. Gyn. 89:377-385, 1964.

58. Van Campenhout, J. and Leduc, B.: Unusual features in the Rokitansky-Kuster-Hauser syndrome. Lancet 2:928, 1971.

59. Winter, J. S. D., Kohn, G., Mellman, W. J. et al.: A familial syndrome of renal, genital, and middle ear anomalies. J. Pedi. 72:88-93, 1968.

Endocrinology

As a result of the occasional observation of corpora lutea in the ovaries at laparotomy (15, 60) and of occasional documentation of ovulatory peaks of plasma LH (16) it has been generally assumed that ovarian function in this disorder is normal. Indeed, the fact that successful pregnancies have been reported following vaginal surgery in several patients who had normal uteri (61-64) indicates that ovarian function in some patients is normal, and recent detailed endocrinological studies support this view. Brown, Kellar, and Matthew investigated three patients with congenital absence of the uterus and vagina and demonstrated cyclical ovarian function in all as assessed by urinary estrogen measurements (60). Fraser and his colleagues subsequently assessed ovarian function in two women with congenital absence of the vagina and uterus by measuring total estrogens, pregnanediol, luteinizing hormone, and follicle stimulating hormone in urine every day for 61 and 88 days respectively; the patterns of hormone excretion were within normal limits with cycle lengths varying from 30 to 34 days (65). D'Albertson, Reschini, Giustina et al. studied pituitary-ovarian relationships in a 26-year old patient by measuring plasma LH, FSH, progesterone, and

estradiol over a 30-day period; cyclic variations of pituitary gonadotropins and gonadal steroids in plasma were similar to those in women with normal menstrual cycles, indicating normal ovulation and normal life-span of the corpus luteum (66). Thus, in view of the fact that ovarian function is generally normal, the significance if any of the reports that 16 of 21 cases in the series of Hauser and Schreiner (7) and two of 14 patients described by Papp, Gardo, Herpay et al. (38) had polycystic ovaries is not clear.

60. Brown, J. B., Kellar, R. and Matthew, G. D.: Preliminary observations on urinary oestrogen excretion in certain gynaecological disorders. J. Ob. Gyn. Brit. Cwlth. 66:177-211, 1959.

61. Baer, J. L. and DeCosta, E. J.: Full-term pregnancy following operation for congenital absence of vagina. Am. J. Ob. Gyn. 54:696-697, 1947.

62. Solomons, E.: Conception and delivery following construction of an artificial vagina. Report of a case. Ob. Gyn. 7:329-331, 1956.

63. Pilkington, J. W.: Pregnancy and spontaneous delivery following operation for congenital atresia of the vagina. Am. J. Ob. Gyn. 78: 804-805, 1959.

64. Jones, H. W. Jr. and Wheeless, C. R.: Salvage of the reproductive potential of women with anomalous development of the Müllerian ducts: 1868-1968-2068. Am. J. Ob. Gyn. 104:348-364, 1969.

65. Fraser, I. S., Baird, D. T., Hobson, B. M. et al.: Cyclical ovarian function in women with congenital absence of the uterus and vagina. J. Clin. Endocr. Metab. 36:634-637, 1973.

66. D'Alberton, A., Reschini, E., Giustina, G. et al.: Plasma gonadotropin and ovarian steroid levels in uterovaginal atresia. Am. J. Ob. Gyn. 117:389-391, 1973.

Cytogenetics and Familial Occurrence

In several large series, the karyotype of affected patients has been that of a normal 46,XX female (15, 35, 38, 67). However, associated chromosomal abnormalities have been reported including XX/XO mosaicism (68), an abnormality of the short arm of one G group chromosome (51) and a 47,XXX/XX mosaicism (69). In the present series all patients had 46,XX karyotypes, but three patients had findings in the karyotype that probably represent normal variations and are not thought to be clinically significant. Case 2 had tandem satellites on chromosome 14; case 5 had a prominent short arm of chromosome 15; case 8 had a prominent short arm of a D group chromosome.

The vast majority of cases have been assumed to be sporadic in nature. Indeed, Bryan, Nigro, and Counseller reported that only one in a hundred cases had a history of other family members with absence of the vagina (13), and Turunen and Unnerus found only one positive family history in more than 200 cases in Finland (28). However, there are now several well

documented instances of familial occurrence of vaginal agenesis in which the diagnosis appears to be unequivocal. Anger, Hemet, and Ensel described a family in which 3 sisters (two of whom were shown to have a 46,XX karyotype) had congenital absence of the vagina (70). The report is of particular interest because abnormalities of the spine and kidneys were documented in only one of the three. Jones and Mermut reported a second family in which congenital absence of the vagina unassociated with other described anomalies occurred in two siblings (71). A third family has also been described by Winter, Kahn, Mellman, et al. in which vaginal agenesis occurred as a part of a more complicated familial syndrome involving the kidneys and the middle ear (59).

The present series includes another instance of clear-cut occurrence of congenital absence of the vagina in siblings (Fig. 2A). In a second family in the present series (Fig. 2B) the index case had congenital absence of the kidney, congenital absence of the vagina, and severe thoracolumbar scoliosis, whereas a sister had scoliosis but a normal vagina, uterus, and kidneys and a maternal aunt had a double uterus. Thus, in the familial cases, variable expressivity of the defect appears to be common. The present family together with that of Winter et al. (59) raises the interesting possibility that the variability of expression might include other abnormalities of the genital tract such as a double uterus (72, 73) and instances in which skeletal abnormalities only could be present. A third patient (Case 4) reported that her mother has severe scoliosis, but this family was not available for study. The presence of clear-cut familial occurrence in one (or two) families in the present series is consistent with several different interpretations. One, some cases may be due to a hereditary abnormality, whereas the remainder are the result of some other type of developmental defect. Two, all cases may result from a mutant gene, but due to natural selection against the transmission of the gene familial cases are unusual. Three, the fact that congenital absence of the vagina may represent only one manifestation of a variably expressed genetic defect may imply that in most family histories ascertainment has not been appropriate so that the real frequency of familial involvement has been underestimated.

67. Capraro, V. J. and Cohen, M. M.: Cytogenetic analysis of patients with developmental anomalies of the Müllerian ducts. Ob. Gyn. 33: 647-648, 1969.

68. Stott, R. B., Cameron, J. S., Ogg, C. S. et al: XO/XX mosaicism in the Rokitansky-Kuster-Hauser syndrome. Lancet 2:1380-1381, 1971.

69. Linquette, M., Gasnault, J. P., Dupont-Lecompte, J. et al.: Le syndrome de Rokitansky-Kuster-Hauser et les syndromes voisins d'aplasie utero-vaginale. Rev. Franc. Endocrinol. Clin. 9:41-60, 1968.

70. Anger, D., Hemet, J. and Ensel, J.: Forme familiale du syndrome de Rokitansky-Kuster-Hauser. Bull. Fed. Soc. Gyn. et Obst. 18:229-234, 1966.

71. Jones, H. W., Jr., and Mermut, S.: Familial occurrence of congenital absence of the vagina. Am. J. Ob. Gyn. 114:1100-1101, 1972.

72. Woolf, R. B. and Allen, W. M.: Concomitant malformations. The frequent, simultaneous occurrence of congenital malformations of the reproductive and urinary tracts. Ob. Gyn. 2:236-265, 1953.

73. Semmens, J. P.: Congenital anomalies of female genital tract. Ob. Gyn. 19:328-350, 1962.

If one assumes that absence of the vagina, spine abnormality, and developmental defects of the urinary tract may be variable and independent manifestations of the same mutant gene, the question should then be posed as to whether additional defects could be manifestations of the same abnormality. First, it is exceedingly interesting in this regard that a third of infants with congenital absence of one kidney also have abnormalities of the genital tract (18), that in bilateral renal aplasia the most frequent associated anomalies are absence of the uterus and vagina with normal Fallopian tubes or absence of the vas, epididymis, and seminal vesicles (74), and that bilateral and unilateral renal aplasia can occur in the same family (59, 74). It is conceivable that a significant fraction of individuals with the Mayer-Rokitansky-Kuster-Hauser abnormality may not survive as the result of such lethal manifestation of the mutant gene. Second, the fact that one patient with typical congenital absence of the vagina had an aunt with a double uterus suggests that other developmental anomalies of the genital tract might also be manifestations of the same underlying defect (72, 73). Finally, the question may be posed as to what phenotype would be present in males affected with the same abnormality; the most analogous syndrome in males is congenital absence of the vas deferens (75-79), a disorder that is also associated with a high frequency of congenital absence of the kidneys (80). Although no family has yet been reported in which both males and females are affected, the possibility should be kept in mind that these two syndromes in men and women might have a unitary origin. Thus, the argument can be made that family histories in these cases should be probed for instances of isolated skeletal and renal abnormalities, for spontaneous abortions that might result from congenital absence of both kidneys and for involvement of male relatives. It is possible that the discordance of vaginal agenesis in identical twins is the result of variable manifestations of an underlying genetic defect rather than to a non-genetic etiology for the abnormality (81). It follows that if congenital absence of the vagina can represent a variable manifestation of a pleotrophic genetic defect, then the frequency of family involvement may have been underestimated.

74. Kohn, G. and Borns, P. F.: The association of bilateral and unilateral renal aplasia in the same family. J. Pedi. 83:95-97, 1973.

75. Michelson, L.: Congenital anomalies of the ductus deferens and epididymis. J. Urol. 61:384-390, 1949.

76. Young, D.: Bilateral aplasia of the vas deferens. Br. J. Surg. 36: 417-418, 1949.

77. Foss, G. L. and Miller, A.: Aplasia of the vasa deferentia as a cause of sterility. Lancet 2:737, 1950.

78. Sandler, B.: Sterility due to congenital absence of the vasa. Lancet 2:736-737, 1950.

79. Dubin, L. and Amelar, R. D.: Etiologic factors in 1294 consecutive cases of male infertility. Fertility and Sterility 22:469-474, 1971.

80. Ochsner, M. G., Brannan, W. and Goodier, E. H.: Absent vas deferens associated with renal agenesis. J. Am. Med. Assoc. 222:1055, 1056, 1972.

81. Lischke, J. H., Curtis, C. H. and Lamb, E. J.: Discordance of vaginal agenesis in monozygotic twins. Ob. Gyn. 41:920-924, 1973.

Embryogenesis

The fundamental issue in regard to the embryogenesis is whether the developmental abnormalities of the genital tract, the urinary system, and the skeleton can be explained by some common lesion. It is interesting in this regard to consider the normal embryogenesis of the internal genitalia of the female which, like the male internal accessory organs of reproduction and the ureters, bladder, and renal pelvis of both sexes, are derived ultimately from the mesonephric kidney system (82, 83). This sequence is summarized schematically in Figure 3.

FIGURE 3. THE ROLE OF THE MESONEPHRIC KIDNEY SYSTEM IN THE EMBRYOGENESIS OF THE UTERUS AND VAGINA, THE MALE ORGANS OF ACCESSORY REPRODUCTION, AND THE URINARY TRACT IN BOTH SEXES.

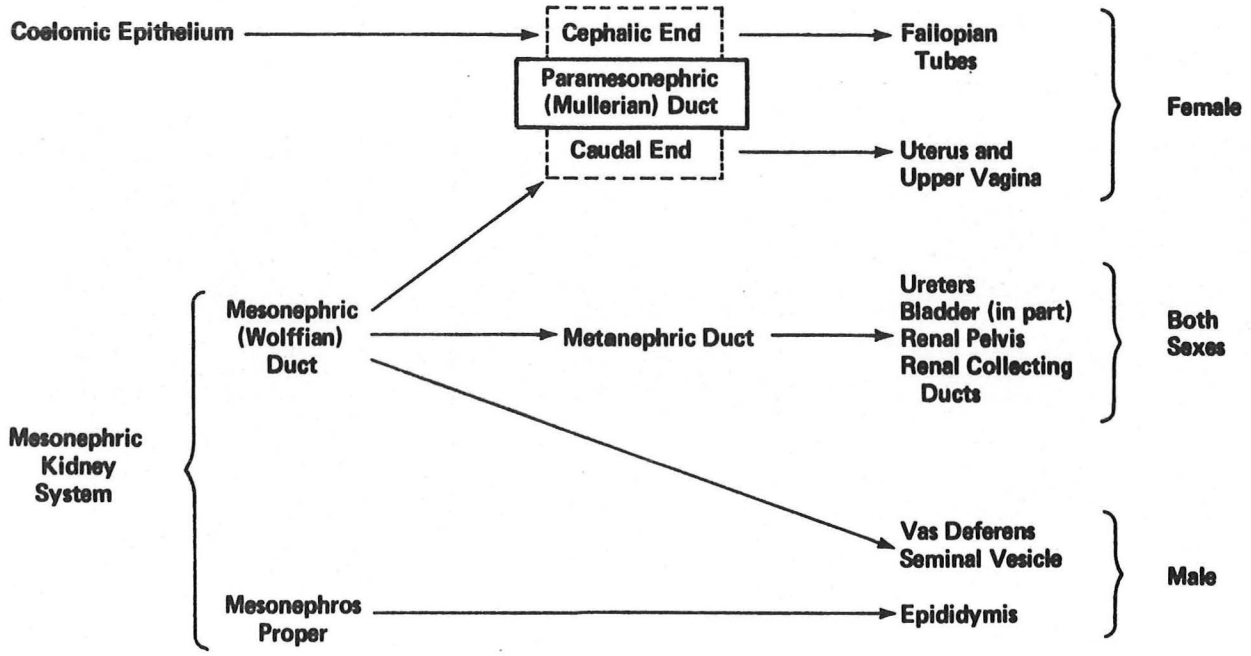

At approximately 7-8 mm (5 weeks) development in the human embryo the mesonephric system consists of a mesonephric kidney (mesonephros proper) and a mesonephric or Wolffian duct that connects the mesonephric kidney with the urogenital sinus. The Wolffian duct is the anlage of the ureteric bud that will eventually provide the excretory ducts for the final (metanephric) kidney in both sexes, of Gartner's duct in the female and of the vas deferens and seminal vesicles in the male. At approximately 10 mm of development in the embryos of both sexes the development of a second (paramesonephric or Mullerian) duct commences. The origin of the Mullerian duct, which is the anlage of the uterus and vagina (in part), has been studied in considerable detail by Gruenwald (84-87). In essence it has two components - a cephalic or anterior portion that is derived from the coelomic epithelium and gives rise to the Fallopian tubes and a caudal end that is probably derived from the Wolffian duct and gives rise to the uterus (84, 87). At 10 mm in both sexes an evagination appears in the coelomic epithelium just lateral to the mesonephros proper (88). This evagination (which will ultimately form the abdominal ostia of the Mullerian duct and the Fallopian tubes) develops into a tubular structure, and the caudal end becomes so intimately connected with the Wolffian duct that no basement membrane separates their epithelium. Whether the Mullerian duct "splits" off from the Wolffian duct in its later caudal development into an independent duct system that empties into the urogenital sinus or whether the Wolffian duct simply acts as a "guide" for subsequent Mullerian duct development is uncertain. It is clear, however, that Mullerian duct development cannot take place in the absence of the Wolffian duct.

Although the evidence is very straightforward that the cephalic end of the Mullerian duct is the anlage of the fallopian tubes and that the caudal portions of the Mullerian duct fuse (in humans) to form the uterus, the exact embryogenesis of the vagina is not so clear. Indeed, a major uncertainty has existed as to the magnitude of the contributions of the urogenital sinus and the Mullerian duct to its development (89-91). It is established that the fusion of the caudal end of the Mullerian duct with the urogenital sinus (at about 30 mm development) is followed by a major epithelial proliferation and elongation that results in the formation of an initially solid vaginal plate. The vaginal plate in turn canalizes beginning at the 150 mm stage to form the vagina proper (89). Although Bulmer has concluded that the cellular origin of the vaginal plate is principally from the urogenital sinus (91), interaction of the Mullerian duct with the urogenital sinus is essential for normal vaginal development. The Wolffian duct is thought to play no role in the embryogenesis of the vagina (91, 92). The forces that regulate the development of a normal vagina and uterus in the female embryo are unclear, but it is generally believed that hormonal secretions of the ovary are not involved in this process (93).

82. Patten, B. M.: Human Embryology. 2nd Ed., New York, McGraw-Hill Book Co., 1953.

83. Hamilton, W. J., Boyd, J. D. and Mossman, H. W.: Human Embryology. Baltimore, Williams and Wilkins Co., 1962, p. 267.

84. Gruenwald, P.: The relation of the growing Mullerian duct to the Wolffian duct and its importance for the genesis of malformations. Anat. Rec. 81:1-19, 1941.

85. Gruenwald, P.: Developmental basis of regenerative and pathologic growth in the uterus. Arch. Path. 35:53-65, 1943.

86. Gruenwald, P.: Mechanisms of abnormal development. II. Embryonic development of malformations. Arch. Path. 44:495-543, 1947.

87. Gruenwald, P.: Growth and development of the uterus: The relationship of epithelium to mesenchyme. Ann. N. Y. Acad. Sci. 75:436-440, 1959.

88. Potemkina, D. A., Grebenshchikova, V. I. and Korosteleva, L. I.: Interaction of cells of Wolffian duct and mesothelium during initial growth period of Mullerian ducts in the axolotl (Ambystoma mexicanum). Sov. J. Dev. Biol. 2:311-322, 1971.

89. Koff, A. K.: Development of the vagina in the human fetus. Contributions to Embryology 140:61-90, 1933.

90. Politzer, G.: Zur normalen und abnormen entwicklung der menschlichen scheide. Anat. Anz. 102:271-278, 1955.

91. Bulmer, D.: The development of the human vagina. J. Anat. 91:490-509, 1957.

92. Bengmark, S. and Forsberg, J.-G.: On the development of the rat vagina. Acta Anat. 37:106-125, 1959.

93. Jost, A.: The role of fetal hormones in prenatal development, in Harvey Lectures. Series 55, New York and London, Academic Press, 1961, p. 201.

The embryogenesis of the Mayer-Rokitansky-Kuster-Hauser syndrome is thus of considerable interest. The most common finding consists of normal ovaries and fallopian tubes with only solid nubbins for uterine horns and no vagina whatsoever. This is the precise lesion that would be predicted if the initial phase of Mullerian duct development, namely the formation of the cephalic end from the coelomic epithelium, were normal but the subsequent development along the Wolffian duct were impaired so that the uterine and vaginal segments of the Mullerian duct are absent or incomplete. Since the Wolffian duct is also the anlage of metanephric duct, it follows that if the fundamental defect were in the Wolffian duct itself, the coexistence of the urinary tract abnormalities (principally renal absence and ectopia) with the defects in the uterus and vagina could result from a single abnormality. Furthermore, from this model one would predict that identical embryonic defects in the Wolffian ducts in male embryos would result in the typical syndrome of congenital absence of the vas deferens with or without renal disease (75-80).

The question must then be posed as to how the skeletal abnormalities can be fitted into this over-all schema. It is of interest that the principal skeletal defect involved the spine, that the embryonic defect in the urogenital tract can be pinpointed at about the 10-11 mm stage of development, and that the fundamental problem is probably in the mesoderm (which also gives rise to mesonephros). At approximately the same stage of development the vertebrae are forming from adjacent mesodermal cell concentrations at roughly the same somite levels as those of the mesonephros (82). Thus, it seems reasonable to suggest that some defect in the organization of the mesoderm at approximately the 10-11 mm stage of development could cause the skeletal abnormalities as well as defective mesonephric development and the subsequent abnormalities in the kidneys and genitalia. If this construction is true and if as suggested from the familial studies the different phenotypes are the result of variable expressivity of one mutant gene, it is also possible that such defects can cause bilateral absence of the kidney and thus be lethal. If so, the clinical disorder in men and women represents only a portion of the true incidence of the disorder. The molecular nature of a defect in mesoderm that could result in such a spectrum of abnormalities is of course unknown.

It is also possible that many instances of this birth defect result from non-genetic causes that have not yet been identified. It is of interest in this regard that the administration of oxidized linoleic acid to pregnant rats results in an increased frequency in the offspring of malformations of the urogenital tract, including absence of the vagina (94).

94. Cutler, M. G. and Schneider, R.: Malformations produced in mice and rats by oxidized linoleate. Fd Cosmet. Toxicol. 11:935-942, 1973.

Diagnosis

The fundamental criteria for the diagnosis of the syndrome are outlined in Table I and include primary amenorrhea and a 46,XX karyotype, absence or hypoplasia of the vagina, and evidence of ovulation. It is essential that the diagnosis be established carefully. Because of the problems of differential diagnosis (see below), demonstration that the karyotype is that of a normal female is mandatory. Analysis of the karyotype will also identify most instances of gonadal dysgenesis in which the phenotype overlaps that of the Mayer-Rokitansky-Kuster-Hauser syndrome, particularly those cases that are ascertained prior to puberty (95). In addition to establishing normal ovulatory biphasic body temperature patterns and/or cyclic progesterone production and normal female karyotype, work-up of the urinary tract is also indicated because the presence of a single pelvic kidney may influence the means chosen for repair of the vagina (13, 43).

In the present series, routine laparotomy has not been performed on all patients. Laparoscopy (Case 2 and Ref. 96) and pelvic pneumography (97, 98) have been used to delineate the exact anatomical features of the uterus in some patients. The nature of the uterine remnant in others can be defined by ultrasonographic techniques (99). Sonograms on three patients are presented in Figure 4.

FIGURE 4. SONOGRAMS DEMONSTRATING A SPECTRUM OF UTERINE FINDINGS IN OUR CASES, INCLUDING COMPLETE ABSENCE OF THE UTERUS (CASE 4), A HYPOPLASTIC UTERUS (CASE 1), AND AN INTACT UTERUS WITH A HEMATOMETRA (CASE 7).

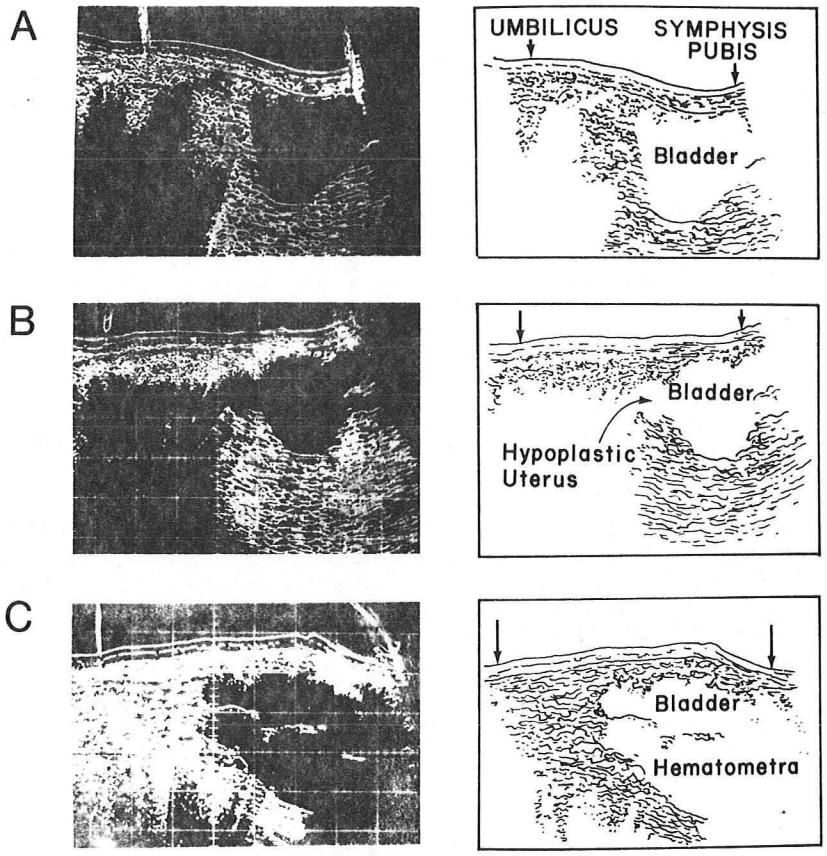

95. Papp, Z., Gardo, S. and Arvay, A.: Zytogenetische differentialdiagnose der scheidenaplasie. Geburtsh. u. Frauenheilk. 31:1239-1242, 1971.

96. Casthely, S., Maheswaran, C. and Levy, J.: Laparoscopy: An important tool in the diagnosis of Rokitansky-Küster-Hauser syndrome. Am. J. Ob. Gyn. 119:571-572, 1974.

97. Armstrong, M. K. and Schreiber, M. H.: Pelvic pneumography in congenital absence of the vagina. Am. J. Roentg., Radium Therapy and Nuclear Medicine 112:607-609, 1971.

98. McDonough, P. G. and Tho, P. T.: Use of pelvic pneumoperitoneum: A critical assessment of 12 years' experience. Sou. Med. J. 67:517-522, 1974.

99. Santos-Ramos, R. and Duenhoelter, J. H.: Diagnosis of congenital fetal abnormalities by sonography. Ob. Gyn. 45:279-283, 1975.

Treatment

Vaginal agenesis can be treated by surgical or non-surgical techniques. Steinmetz has reviewed the early history of surgical construction of the vagina, including the use of skin grafts, loops of bowel, and simple reconstructions with the use of molds (100). Most modern surgical series in this country have utilized a variation of the procedure of McIndoe, who modified prior methods using split-thickness skin grafts to use instead a single large thigh graft around a solid rubber mold for the creation of an artificial vagina (101). With the modification by Counseller and Flor (102), this procedure has been used widely. In a complete departure from the surgical approach, Frank in 1938 described a simple non-operative method for the development of a vaginal depth using repeated applications of pressure against the vaginal dimple with a simple test tube or other plastic dilator (103). In early reviews, Steinmetz (100) and Marshall (104) emphasized the efficacy, safety, and simplicity of this non-operative procedure. However, most published results are difficult to evaluate because of uncertain criteria as to success and because many patients have been followed only for short periods of time. In some there is no description of the depth or dimensions of the resulting vagina, and only the functional criteria of satisfactory intercourse have been utilized as a measure of success.

In 1959 McIndoe reviewed his own experience with 105 patients and described criteria for excellent, satisfactory, and poor results (105). He reported that about 95% of patients had an ultimately satisfactory outcome; early complications included extrusion of the mold requiring re-operation in 19% and urinary infections in 13%. Rectovaginal fistulae complicated the operation in 4% of the group. Failure to have regular intercourse after removal of the mold was associated with the development of marked stenosis of the cavity. A similar success rate of about 80% was noted by Thompson, Wharton, and TeLinde (30) in 32 cases treated by the McIndoe operation who were followed for more than a year. Complications in the latter series included 3 rectovaginal fistulae, 2 urethral lacerations, and one significant postoperative hemorrhage. Unsatisfactory results were attributed to failure to wear the mold as directed or lack of regular intercourse after removing the mold (30).

Cali and Pratt summarized the result in 175 patients treated at the Mayo Clinic, including 123 patients who underwent the McIndoe operation and 44 patients in whom other procedures were used (26). In those 123 patients seven had major complications such as fistulae or hemorrhage, and 10 required secondary operations. In 113 patients who had short-term follow-up, 24 had some contraction of the vagina, and another 24 had frank stenosis. However, 84 of 93 patients reported a satisfactory result in regard to sexual function. In those followed for 10 years or more over half were found to have some contraction, and complete stenosis was present in a fifth. Nevertheless, more than 90% reported good to excellent sexual function. Thus, any evaluation of operative results must distinguish between anatomic and functional criteria.

In reviewing 20 reported cases of vaginal agenesis treated by the Frank non-operative method, Wabreck, Millard, Wilson, et al. (39) found that there were essentially no complications, and functionally satisfactory results were obtained in more than 90%. All patients in the present series who had not sustained surgical repair prior to referral were treated by the non-operative method except Case 7 (CH) who had a uterus that was considered to be potentially functional, and for this reason she was subjected to vaginoplasty. In view of the over-all serious complication rate of at least 5 to 10% in all surgical series, the non-operative approach should probably be attempted initially in most cases. It is likely that continued coitus or instrumental dilatation is essential for maintaining the neo-vagina formed by the non-operative method as well as the surgically constructed vagina. D'Albertson and Santi have suggested that with an initial small dimple repeated intercourse alone may lead to a functionally adequate vagina (106), but the possibility that urethral coitus might occur in such instances should be kept in mind (107).

The cases in which operative treatment is definitely indicated are those infrequent patients in which a well formed uterus is present and in whom the possibility of fertility exists. These individuals usually present shortly after the time of expected menarche due to hematometra and/or retrograde menstruation. In several instances construction of an artificial vagina in such patients has been followed by conception and delivery (61-64). One patient in the present series (case 7) was treated in this manner with the expectation that she might wish to become pregnant in the future.

An interesting aspect of the formation of an artificial vagina is that several authors have reported that the neo-vagina acquires almost all of the characteristics of normal vaginal epithelium including the formation of a stratified squamous epithelium of the mucous membrane type with glycogen production and cornification varying throughout the cycle of estrogen production (108-113) similar to the normal vagina (110). This appears to be true also for the epithelium formed by ingrowth after the Frank procedure as well (111).

100. Steinmetz, E. P.: Formation of artificial vagina. West. J. Surg. Ob. Gyn. 48:169-180, 1940.

101. McIndoe, A. H. and Banister, J. B.: An operation for the cure of congenital absence of the vagina. J. Ob. Gyn. Br. Cwlth. 45:490-494, 1938.

102. Counseller, V. S. and Flor, F. S.: Congenital absence of the vagina. Further results of treatment and a new technique. Surg. Clin. of N. Am. 37:1107-1117, 1957.

103. Frank, R. T.: The formation of an artificial vagina without operation. Am. J. Ob. Gyn. 35:1053-1055, 1938.

104. Marshall, H. K.: Formation of artificial vagina. Experiences with three different corrective procedures. West. J. Surg. Ob. Gyn. 52: 245-255, 1944.

105. McIndoe, A.: Discussion on treatment of congenital absence of vagina with emphasis on long-term results. Proc. Roy. Soc. Med. 52: 952-954, 1959.

106. D'Alberton, A. and Santi, F.: Formation of a neovagina by coitus. Ob. Gyn. 40:763-764, 1972.

107. Taneja, P. P., Heera, D., Gulati, S. M. et al.: Urethral coitus in a case of vaginal agenesis. Br. J. Urol. 45:451, 1973.

108. Ayre, J. E.: Cyclic ovarian changes in artificial vaginal mucosa. Am. J. Ob. Gyn. 48:690-695, 1944.

109. Miller, N. F., Willson, J. R. and Collins, J.: The surgical correction of congenital aplasia of the vagina. An evaluation of operative procedures, end result, and functional activity of the transplanted epithelium. Am. J. Ob. Gyn. 50:735-747, 1945.

110. Masters, W. H.: The sexual response cycle of the human female: vaginal lubrication. Ann. N. Y. Acad. Sci. 83:301-317, 1959.

111. Masters, W. H. and Johnson, V. E.: The artificial vagina: anatomic, physiologic, psychosexual function. West. J. Surg. Ob. Gyn. 69: 192-212, 1961.

Associated Medical Problems

Secondary renal disease is frequent in subjects with developmental abnormalities of the genitourinary tract (21, 22), and as would be expected pyelonephritis is a common occurrence in subjects with congenital absence of the uterus. However, to date no specific effect of congenital absence of the uterus on life span and no primary abnormalities in renal function have been documented. The most serious of the renal abnormalities in the disorder (compatible with life) is the solitary pelvic kidney, and intravenous pyelography is indicated prior to the performance of any pelvic surgery.

A variety of malignancies have been described in the genital tract. These include ovarian carcinoma (27, 113-115), one instance of adenocarcinoma of the cervix in a patient with congenital absence of the vagina and a normal uterus (116), and two cases of carcinoma of the artificial vagina following surgical reconstruction (117, 118). Since the disorder is relatively common, it is possible that there is no increased incidence of malignancy.

Perhaps the most common genital complication is that related to retrograde menstruation in those patients with a well developed uterus; in some instances surgical removal is necessary, and in other instances an artificial vagina may be connected successfully to the uterus. Such an instance is illustrated in Case 7 in the present series.

Kaplan has described the psychological problems associated with congenital absence of the vagina and has emphasized that disturbances of body image and self esteem are common, often associated with reactive depression (119, 120). With adequate treatment and supportive care, however, most patients are able to have adequate sexual relations and to function effectively as well adjusted women (111, 119-121).

112. Iwaszkiewicz, J: Zespol Rokitansky ego-Küstera-Hausera z obustronna przepuklina wargowa zawierajaca nowotworowo zmienione jajniki. Pol Tyg Lek 28:412-414, 1973.

113. Graudenz, M. G.: Teratocarcinoma of the ovary associated with aplasia of the uterus and vagina. Ob. Gyn. 25:741-742, 1965.

114. Iwaszkiewicz, J.: Rokitansky-Kuster-Hauser syndrome with bilateral labial hernia containing ovaries with neoplastic changes. Pol. Tyg. Lek. 28:412-414, 1973.

115. De Ridder, G. and Bigalke, K.-H.: Fall eines Mayer-Rokitansky-Küster-syndroms in kombination mit granulosazelitumor. Geburtsh. u. Frauenheilk, 34:579-581, 1974.

116. Taylor, J. M. and Weed, J. C.: Adenocarcinoma of the cervix associated with multiple pelvic congenital anomalies. Ob. Gyn. 21: 446-469, 1963.

117. Ritchie, R. N.: Primary carcinoma of the vagina following a Baldwin reconstruction operation for congenital absence of the vagina. Am. J. Obst. Gyn. 18:794-799, 1929.

118. Jackson, G. W.: Primary carcinoma of an artificial vagina. Report of a case. Obst. Gyn. 14:534-536, 1959.

119. Kaplan, E. H.: Congenital absence of vagina. Psychiatric aspects of diagnosis and management. N. Y. State J. Med. 68:1937-1941, 1968.

120. Kaplan, E. H.: Congenital absence of the vagina. Psychoanalytic Quart. 39:52-70, 1970.

121. David, A., Carmil, D., Bar-David, E. et al.: Congenital absence of the vagina. Ob. Gyn. 46:407-409, 1975.

Summary of the M-R-K-H Syndrome

Congenital absence of the vagina is a common cause of primary amenorrhea. The present series of such patients is notable in two regards. First, the incidence of associated developmental abnormalities of the urinary tract (8/14) is greater than the over-all incidence of 30% reported in most series. The common renal abnormalities are absent and ectopic kidneys. In addition, the frequency of skeletal abnormalities (primarily of the spine) in 7 of the patients is greater than the 12% incidence observed in previous series. We attribute these differences to a more uniform evaluation of the patients in the present study. Second, the family histories were of interest in two instances. In one family, two siblings had congenital absence of the vagina and minor kidney involvement and one of the two also had skeletal abnormalities. In the second family, one individual had congenital absence of the uterus, congenital absence of the kidney, and severe thoraco-lumbar scoliosis whereas a sister had scoliosis but normal kidneys and vagina. Considered together, these findings suggest that the disorder may represent the variable manifestation of a single underlying genetic defect that can manifest itself as any combination of vertebral, renal, and genital abnormalities. If this is the case, some affected individuals may have lethal manifestations of the defect such as absence of both kidneys, and in males the phenotype may be expressed as congenital absence of the vas deferens. It is not possible to exclude the alternate possibility that some cases may result from multifactoral etiologies rather than a single gene defect.

Whatever the underlying etiology, however, on embryological grounds it seems likely that the defect involves mesodermal development early in embryogenesis (probably around the 10 mm stage) that results in defects in the development of the vertebrae and the mesonephric kidney and that the abnormality of the mesonephros leads both to abnormalities in the paramesonephros (uterus and vagina) and in the metanephric kidney system. Two forms of treatment are available, a non-operative technique and surgical correction, both of which are associated with a high success rate.

Differential Diagnosis of Primary Amenorrhea

The question is, how does this disease fit into the overall picture of primary amenorrhea. Ross and Vande Wiele have summarized the etiological basis for primary amenorrhea in 538 women as described in nine large case series in the literature (121):

TABLE 6

ETIOLOGY OF PRIMARY AMENORRHEA IN 538 WOMEN

CAUSE	PER CENT	
GONADAL	57%	
GONADAL DYSGENESIS		29%
MALE PSEUDOHERMAPHRODITISM		11%
POLYCYSTIC OVARIES		8%
MISCELLANEOUS		9%
EXTRAGONADAL	38%	
CONGENITAL ABSENCE OF THE VAGINA		18%
HYPOGONADOTROPHIC STATES		8%
DELAYED MENARCHE		6%
MISCELLANEOUS		6%
UNKNOWN	4	

The list of "miscellaneous" causes is quite extensive and includes the "resistant ovary" syndrome, adrenal disease, inflammatory diseases of the pelvis, and imperforate hymen, all of which are rare.

122. Ross, G. T. and R. L. Vande Wiele. The Ovaries. Ch. 1 in Textbook of Endocrinology, ed. by R. H. Williams. Philadelphia: W. B. Saunders Co., 1974, 368-422.

Two detailed outlines for the workup of these patients have been published (1, 122), but it is apparent from the data in Table 7 that the vast majority of cases can be diagnosed on the basis of history and physical findings and on occasion with the aid of the karyotype and gonadotropins.

TABLE 7. CHARACTERISTIC CLINICAL FEATURES OF THE COMMON CAUSES OF PRIMARY AMENORRHEA

Disorder	Female Secondary Sex Characteristics	Vagina	Cervix	Normal Ovulation	Karyotype	Virilization	Gonadotropins	Withdrawal Bleeding After Progesterone
Gonadal								
Gonadal dysgenesis	-	+	+	No	Variable	Rare	High	No
Male pseudohermaphroditism	±	±	-	No	46XY	Occasional	Usually high	No
Polycystic ovaries	+	+	+	No	46XX	Common	Slightly high	Yes
Extragonadal								
Congenital absence of the vagina	+	±	-	Yes	46XX	No	Normal	No
Hypogonadotrophic states	-	+	+	No	46XX	No	Low	No
Delayed menarche	-	+	+	No	46XX	No	Generally low	Yes

The data from our own hospital and that published in the gynecological literature indicate that congenital absence of the vagina is second only to gonadal dysgenesis as a cause of primary amenorrhea. Considering its frequency and the associated medical problems it is not clear why so little attention has been directed to it in the medical literature.