

Well Differentiated Neuroendocrine Tumors past, present and future

Internal Medicine Grand Rounds
University of Texas Southwestern Medical Center
December 8, 2017

Yull E. Arriaga, MD¹
Associate Professor
Division of Hematology Oncology

¹ This is to acknowledge that Yull E. Arriaga, M.D. has disclosed that he does have speaking engagement interests with commercial concerns related directly or indirectly to this program. Dr. Arriaga will not be discussing off-label uses in his presentation.

Yull E. Arriaga, MD
Associate Professor
Division of Hematology Oncology
Harold C. Simmons Comprehensive Cancer Center
University of Texas Southwestern Medical Center

Dr. Arriaga is focused on giving his patients better cancer treatments and improving their quality of life. He believes that a multidisciplinary approach is the best way to treat patients with cancer. He specializes in Genitourinary (GU) and Gastrointestinal (GI) Medical Oncology. He is vice-chair of the Data and Safety Monitoring Committee (DSMC) at the Simmons Cancer Center. He is the principal investigator of several clinical trials in genitourinary medical oncology.

Purpose and Overview

The purpose of this presentation is to provide a summary and discussion of the current definition, epidemiology, pathophysiology, prognostic factors, new imaging modalities and level 1 evidence systemic therapies for patients with well differentiated pancreatic and non-pancreatic neuroendocrine tumors. A list of priorities for future clinical research is mentioned at the end of the presentation.

Educational Objectives

At the conclusion of this lecture, the listener should be able to:

1. Understand the definition and epidemiology of well differentiated neuroendocrine tumors.
2. Describe the role of somatostatin, somatostatin receptors and serotonin in well differentiated neuroendocrine tumors.
3. Describe clinical and molecular prognostic factors in well differentiated neuroendocrine tumors
4. Understand the role of ⁶⁸Gallium Dotatate PET scan in the evaluation of patients with well differentiated neuroendocrine tumors.
5. Describe level 1 evidence systemic therapies for metastatic well differentiated neuroendocrine tumors.
6. Describe the role of telotristat for the treatment of carcinoid diarrhea.

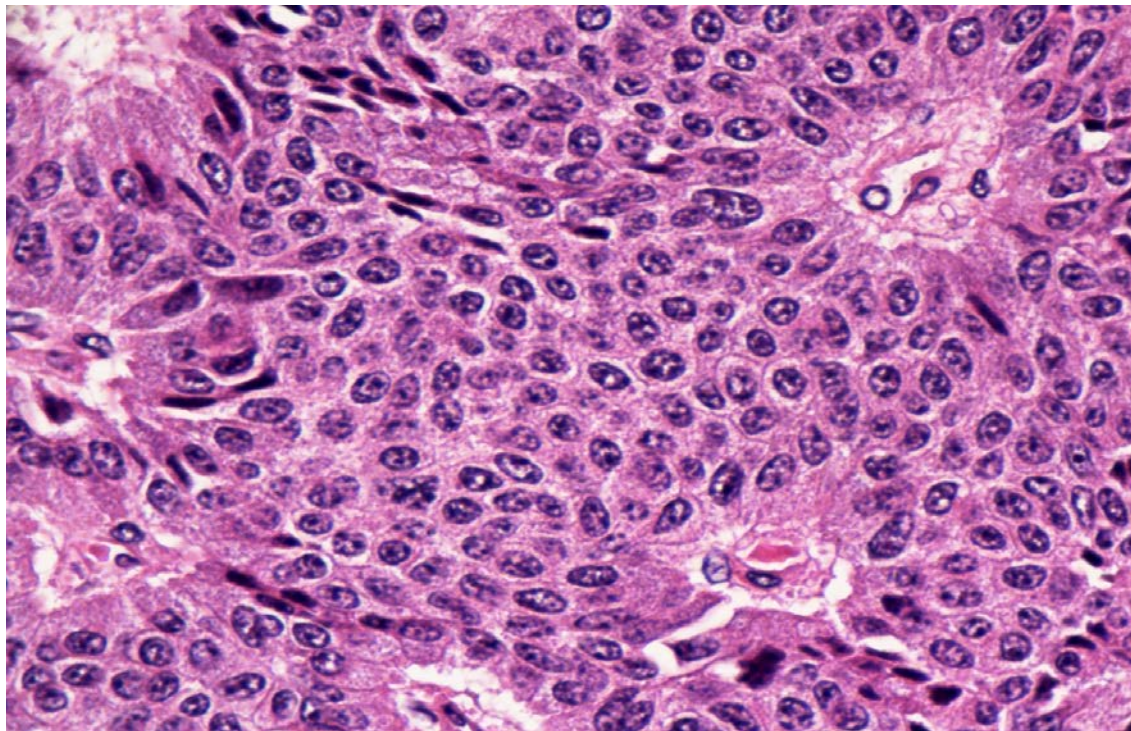
WELL DIFFERENTIATED NEUROENDOCRINE TUMORS PAST PRESENT AND FUTURE

I. INTRODUCTION

Definition

Neuroendocrine tumors (NETs) are a heterogeneous group of epithelial neoplasms with neuroendocrine differentiation arising in different locations of the body. At least fifty percent of NETs arise from the diffuse neuroendocrine cellular system of the gastrointestinal tract and pancreatic gland. These are referred as gastroenteropancreatic neuroendocrine tumors (GEPNETs). Most patients with GEPNETs have distant metastatic disease at the time of presentation. Common sites of metastases include liver, abdominal lymph nodes, lungs and bones. A majority of GEPNETs overexpress somatostatin receptors (SSTRs). They can be associated with excess secretion of peptide hormones and bioactive amines like serotonin leading to carcinoid syndrome and other endocrine syndromes. Histologically, the majority of GEPNETs are well differentiated, low grade tumors with a characteristic organoid nesting pattern of uniform cells with a moderate amount of eosinophilic cytoplasm and finely granular nuclear chromatin (Figure 1).

Figure 1. Well differentiated, low grade neuroendocrine tumor of the ileum.



Pancreatic Neuroendocrine Tumors-PNETs and Non-Pancreatic NETs

There are multiple classifications of NETs. A clinically useful classification of these malignancies separates them into pancreatic neuroendocrine tumors (PNETs) and non-pancreatic NETs (Table 1). Non-pancreatic include NETs of the mid-gut and lung. The biology and clinical course of PNETs and non-pancreatic NETs is different. In general, PNETs are associated with a more aggressive clinical course and shorter overall survival¹. Current clinical trials evaluating new therapies for GEPNETs separate them into PNETs and non-pancreatic NETs.

Table 1. Clinical Classification of Neuroendocrine Tumors

Non-Pancreatic NETs	Pancreatic Neuroendocrine Tumors
Mid-gut NETs	PNETs
Lung NETs	

Carcinoid Tumors a Brief Historic Perspective

The first pathologic description in the literature of what we now know as NETs was made by German pathologist Dr. Otto Lubarsch in 1888². He described 2 male autopsy cases of multiple tumors involving the distal ileum. Dr. Lubarsch failed to recognize these tumor as a distinct clinical entity. In 1907, another German pathologist, Dr. Siegfried Oberndorfer at the University of Munich was the first physician to adequately characterize these tumors as a distinct clinical entity. He used the term "karzinoide" or "benign carcinomas" to describe these malignancies referring to their indolent behavior³. Now, the term "carcinoid tumor" is used less frequently. In current literature "carcinoid tumors" are used in general when referring to mid-gut NETs.

Epidemiology of Neuroendocrine Tumors

The incidence and prevalence of GEPNETs is increasing in the US. A retrospective study based on review of the Surveillance, Epidemiology and End Results (SEER) program showed a 6.4-fold increase in the incidence of GEPNETs from 1.09 cases/100,000 in 1973 to 6.98 cases/100,00 in 2012⁴. The reason for this increase is likely caused by earlier disease diagnosis and stage migration. The indolent clinical course of well differentiated GEPNETs make them prevalent malignancies. The estimated 20-year limited duration prevalence of GEPNETs as of January 1, 2014 was 171,321 cases⁴. The yearly prevalence of GPNETs is higher than the yearly prevalence of adenocarcinomas of the stomach and pancreas combined in the US.

In the past 10 years, there has been an improvement in overall survival (OS) for patients with GEPNETs. A 29% relative improvement in OS for all patients with GEPNETs and a 21% relative improvement in OS for metastatic GEPNETs was seen in the US for the period 2009-2012 compared to 2000-2004⁴. This improvement most likely reflects, earlier diagnosis of these neoplasms, better care and earlier introduction of systemic therapies like somatostatin analogues (SSA) in patients with metastatic disease. Pancreatic neuroendocrine tumors have a more rapid progression with a median overall survival (OS) of 24 months compared to 56 months in patients with non-pancreatic NETs¹. Given the high prevalence of GEPNETs, it is important for general internists to be familiar with the clinical presentation and management of patients with these heterogeneous group of malignancies.

Nomenclature of Neuroendocrine Tumors

Multiple nomenclature systems to describe the histologic patterns and grade of GEPNETs exist. This creates confusion in the diagnosis, patient management and interferes with the development of clinical trials and epidemiologic studies. The most useful parameters to determine the clinical behavior of GEPNETs include:

- Histologic morphology/tumor differentiation: well vs poorly differentiated
- Tumor grade or proliferative potential measured by:
 - Immunohistochemistry (IHC) marker Ki-67
 - Mitotic rate per 10 high power field (HPF).

The above parameters are included in the World Health Organization (WHO) nomenclature of GEPNETs (Table 2).^{5,6} In addition, the IHC markers synaptophysin and chromogranin should be included in every pathology report. Most patients with non-pancreatic NETs have low grade tumors (Ki-67 < 3% and/or < 2 mitoses/10HPF). Intermediate grade (Ki-67 3 to 20% and/or 2 to 20 mitoses per HPF) or high grade (Ki-67 > 20% and / or > 20 mitoses/HPF) are not uncommon among patients with PNETs

Table 2 World Health Organization Classification of Gastroenteropancreatic Neuroendocrine Tumors

WHO Nomenclature of GEP NETs

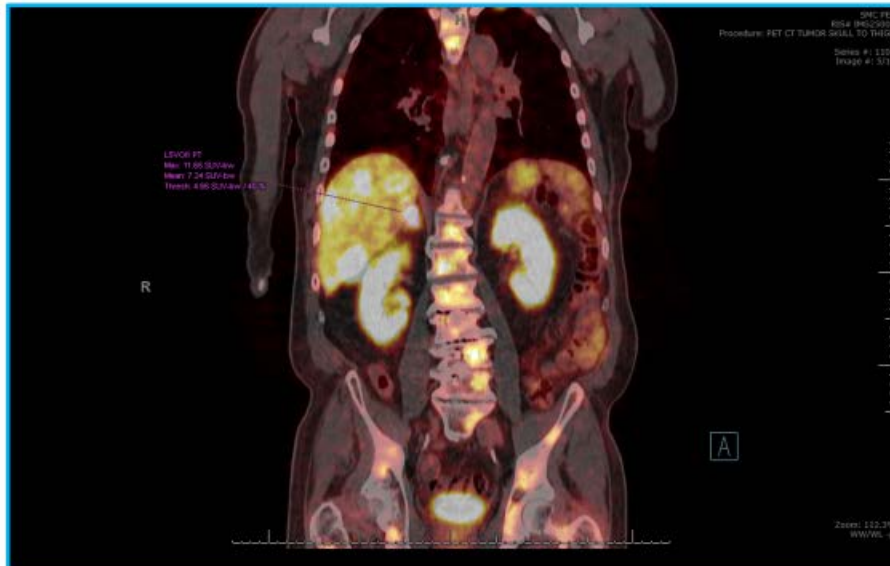
Differentiation and Grade	Mitotic Count (10/HPF)	Ki-67 Index (%)	Traditional Classification	WHO Classification
Well Differentiated				
Low Grade (Gr 1)	< 2	<3	Carcinoid, Islet Cell, PNET	Neuroendocrine Tumor Gr 1
Intermediate Grade (Gr 2)	2-20	3-20	Carcinoid, Atypical Carcinoid, Islet Cell, PNET	Neuroendocrine Tumor Gr 2
Poorly Differentiated				
High Grade (Gr 3)	> 20	> 20	Small Cell Carcinoma	Neuroendocrine Carcinoma Gr 3 Small Cell
High Grade (Gr 3)	> 20	>20	Large Cell Carcinoma	Neuroendocrine Carcinoma Gr 3 Large Cell

II.SOMATOSTATIN, SOMATOSTATIN RECEPTORS (SSTRs), SEROTONIN AND CARCINOID SYNDROME

Knowledge of the basic physiology of somatostatin, somatostatin receptors (SSTRs) and serotonin synthesis and secretion are key to understand the manifestations, clinical course and management of patients with GEPNETs. A majority of well differentiated GEPNETs express SSRTs in the cell surface. Excess production of hormones and bioactive amines like serotonin leading to different endocrine syndromes including carcinoid syndrome is a common feature of these group of malignancies. Somatostatin analogues (SSAs) are used in the diagnosis and treatment of GEPNETs.

Figure 2. Somatostatin Receptor Positive Metastatic Pancreatic Neuroendocrine Tumor. Liver and Skeletal Metastases. ^{68}Ga Gallium Radiolabeled Somatostatin Analogue Positron Emission Tomography (PET) Scan.

^{68}Ga DODATE PET Scan Well differentiated PNET



Somatostatin: An Anti-Neoplastic Hormone

Somatostatin is the universal “endocrine off-switch” hormone of the body. It was isolated and characterized by Nobel Laureate Dr. Roger Guillemin at the Salk Institute in 1972⁷. Native somatostatin has 14 (SSST-14) and 28 (SST-28) amino acid active biologic forms with a half-life of 1 to 3 minutes. In contrast SSAs like octreotide have a half-life of 90 minutes. Deposit preparations of SSAs administered every 4 weeks like octreotide acetate and lanreotide are available in the US for treatment of carcinoid syndrome and for control of metastatic or unresectable GEPNETs. In addition to its hormonal inhibitory function there is increasing evidence that somatostatin has anti-neoplastic effects:

- Anti-proliferative
- Anti-angiogenic
- Anti-inflammatory

Somatostatin and SSAs activate somatostatin receptors (SSTRs) which are G-protein couple receptors bound to the cell membrane. Five different SSTRs have been identified in humans⁸. Activation of SSTRs results in decrease intracellular cAMP⁹. There is evidence that activation of specific SSTRs by somatostatin or SSAs result in stimulation of transmembrane protein tyrosine phosphatases (PTPs)¹⁰. Stimulation of PTPs may result in:

- Cell cycle arrest and growth inhibition through induction of the retinoblastoma (RB) tumor suppressor protein and p21 (activation of SSTR1, SSTR2, SSTR4 and SSTR5)
- Induction of apoptosis through activation of p53 and BAX (activation of SSTR3)

Serotonin and Carcinoid Syndrome

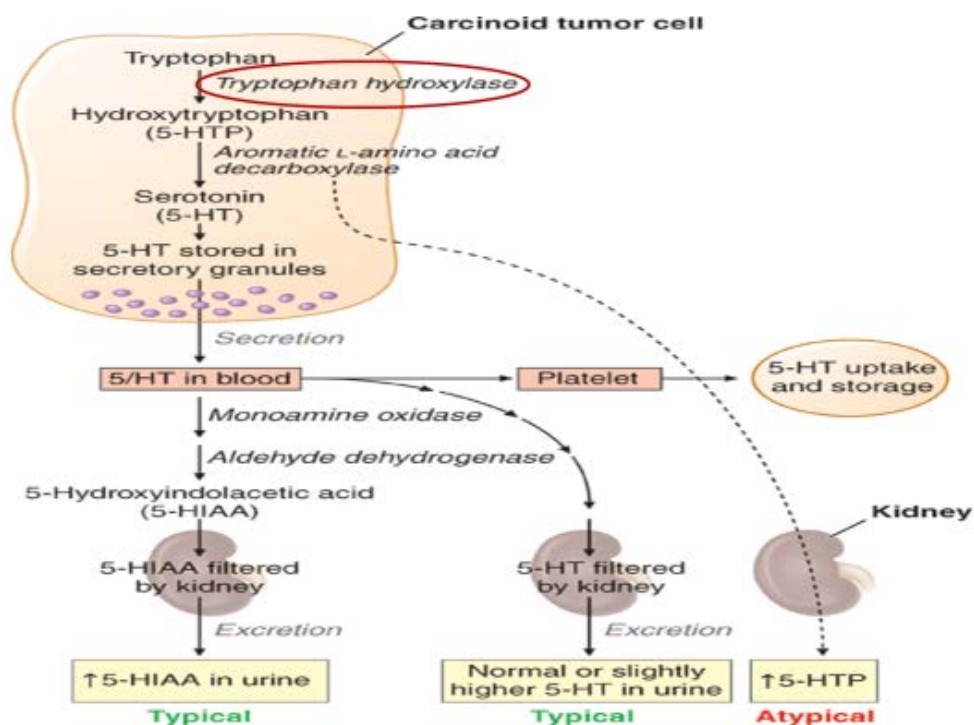
Patients with GEPNETs can present with carcinoid syndrome. Manifestations of carcinoid syndrome include acute and chronic facial flushing, skin erythema, diarrhea, pruritus; feeling of warmth, lacrimation, facial or conjunctival edema, palpitations and others.

Carcinoid syndrome is caused by excess secretion of multiple bioactive amines like serotonin, histamine, dopamine, substance P, substance K, ACTH, prostaglandin and others by neuroendocrine malignant cells. Serotonin plays a central role in the development of carcinoid syndrome. Figure 2¹¹ shows the steps for serotonin synthesis. The rate limiting step in the synthesis of serotonin is the hydroxylation of L-tryptophan to hydroxy-tryptophan by tryptophan hydroxylase.

Pharmacologic control of carcinoid syndrome can be achieved by decreasing serotonin levels. This can be accomplished by:

- Decreasing the secretion of serotonin by malignant neuroendocrine cells by activating SSTRs with SSAs like octreotide¹² or lanreotide¹³
- Decreasing the production of serotonin by neuroendocrine cells through inhibition of tryptophan hydroxylase by medications like telotristat ethyl¹⁴

Figure 2. Synthesis of serotonin



Source: Longo DL, Fauci AS, Kasper DL, Hauser SL, Jameson JL, Loscalzo J: *Harrison's Principles of Internal Medicine*, 18th Edition; www.accessmedicine.com
Copyright © The McGraw-Hill Companies, Inc. All rights reserved.

III.CELLULAR SIGNALING PATHWAYS AND GENOMIC ALTERATIONS IN GEPNETs

Several cellular signaling pathways are abnormally activated in GEPNETs. Additionally, specific genomic alterations identified in these malignancies lead to malignant cell proliferation, invasion and survival. Below are some of the most important activated cellular signaling pathways and genomic alterations found in GEPNETs:

- Activation of PI3K/Akt/mTOR
- Angiogenesis through vascular endothelial growth factor receptor (VEGFR)
- Abnormal cell cycle regulators: mutation or deletions of CDK1NB
- Tumor growth factor beta / alterations in SMAD genes¹⁵ (Francis JM)
- Mutated genes in pancreatic neuroendocrine tumors: MEN1, DAXX, ARTX¹⁶(Jiao)

IV.CLINICAL PROGNOSTIC FACTORS IN GEPNETs

The most important clinical prognostic factors in patients with neuroendocrine tumors include¹:

- Disease stage: presence or absence of metastases
- Tumor grade
- Age at presentation
- Serum chromogranin A¹⁷

In addition, serum chromogranin A is a useful tumor marker in the management of patients with GEPNETs. In general, the level of serum chromogranin A correlates with the burden of metastatic disease and response to therapy. The secretion of serum chromogranin A by malignant neuroendocrine cells is not pulsatile and is not subjected to first pass metabolism in the liver. To date no predictive factors have been identified in patients with GEPNETs

V.NEW IMAGING MODALITIES FOR GEPNETs

⁶⁸Gallium Radiolabeled Somatostatin Analogue Positron Emission Tomography (PET) – ⁶⁸Ga DODATE PET Scan for Well differentiated GEPNETs

A majority of low grade GEPNETs express somatostatin receptors (SSRs)¹⁸. Clinicians can take advantage of this tumor characteristic by using radiolabeled somatostatin analogues (SSAs) targeting tumor cell SSRs for diagnosis, staging and treatment of GEPNETs. Diagnostic imaging modalities currently approved by the FDA for the evaluation of patients with GEPNETs include:

- ¹¹¹Indium-pentetreotide single photon emission computed tomography (SPECT)/computed tomography (CT) scintigraphy: Diagnostic sensitivity ranges from 65 to 100% depending on site and other tumor characteristics¹⁹
- Fluorodeoxyglucose (¹⁸FDG) PET scan: Enhanced sensitivity for poorly differentiated GEPNETs
- I-metaiodobenzylguanidine (MIBG) scintigraphy
- CT scan and magnetic resonance imaging (MRI): Provides anatomic cross sectional imaging
- Endoscopic ultrasound (EUS): most commonly used in the tumor (T), lymph node (N) and metastasis (M) staging of pancreatic neuroendocrine tumors

A new imaging modality for patients with low grade GEPNETs is PET scanning with somatostatin analogues radiolabeled with the positron emitting isotope ^{68}Ga (^{68}Ga DOTA peptide PET). ^{68}Ga is a single-photon gamma-emitting radiometal ideal for PET scanning. It has a half-life of 1.1 hours as compared to 2.5 days for ^{111}In . Somatostatin analogues radiolabeled with ^{68}Ga used in PET scanning for low grade GEPNETs include:

- ^{68}Ga -DOTANOC: Binds SSRs 2,3,5
- ^{68}Ga -DOTATE (Nespot): Binds SRRs 2, 5
- ^{68}Ga -DOTATOC

A single arm, prospective study of 131 patients with GEPNETs evaluated the diagnostic accuracy of ^{68}Ga -DOTATATE PET/CT, ^{111}In -pentetreotide SPECT/CT and multiphasic CT scan, and/or MRI in a blinded fashion with comprehensive biochemical testing²⁰. The primary endpoint was the rate of detection of lesions by each imaging study. In this study, ^{68}Ga -DOTATATE PET/CT detected 95.1% of lesions (95% CI, 92.4% to 96.8%), anatomic imaging detected 45.3% of lesions (95% CI, 37.9% to 52.9%), and ^{111}In -pentetreotide SPECT/CT detected 30.9% of lesions (95% CI, 25.0% to 37.5%). The difference of lesion detection rate between imaging modalities was statistically significant ($p < 0.01$). In 4 of 14 patients (28.6%), ^{68}Ga -DOTATATE PET/CT found a previously unknown primary tumor. In addition, ^{68}Ga -DOTATATE PET/CT detected primary GEPNET, lymph node, and distant metastases correctly in 72 of 113 lesions (63.7%) when compared with histopathology, with 22.1% and 38.9% detected correctly by using ^{111}In -pentetreotide SPECT/CT and anatomic imaging, respectively. Based on results of ^{68}Ga -DOTATATE PET/CT, 43 of 131 patients (32.8%) had a change in management recommendation. In patients with carcinoid symptoms with negative biochemical testing, ^{68}Ga -DOTATATE PET/CT detected lesions in 65.2% of patients, 40% of which were detected neither by anatomic imaging nor by ^{111}In -pentetreotide SPECT/CT²⁰.

In summary, as compared to ^{111}In -pentetreotide SPECT/CT scintigraphy or to CT scan/MRI, ^{68}Ga DOTATATE PET scan in patients with low grade GEPNETs is associated with:

- Higher sensitivity for staging
- Higher sensitivity for assessment of extent of metastatic disease
- Higher detection rate of primary tumor
- Appropriate selection of treatment in symptomatic patients even in the absence of biochemical evidence of disease (normal serum chromogranin A or normal 5HIAA in 24-hour urine)
- Change in management recommendations

In June 2016 FDA approved ^{68}Ga -DOTATE (Netspot) for PET imaging for somatostatin receptor positive GEPNETs. ^{68}Ga -DOTATE (Netspot) PET scanning has been available at UT Southwestern Medical Center since April 2017.

VI.TREATMENT OF ADVANCED AND METASTATIC WELL DIFFERENTIATED GEPNETS

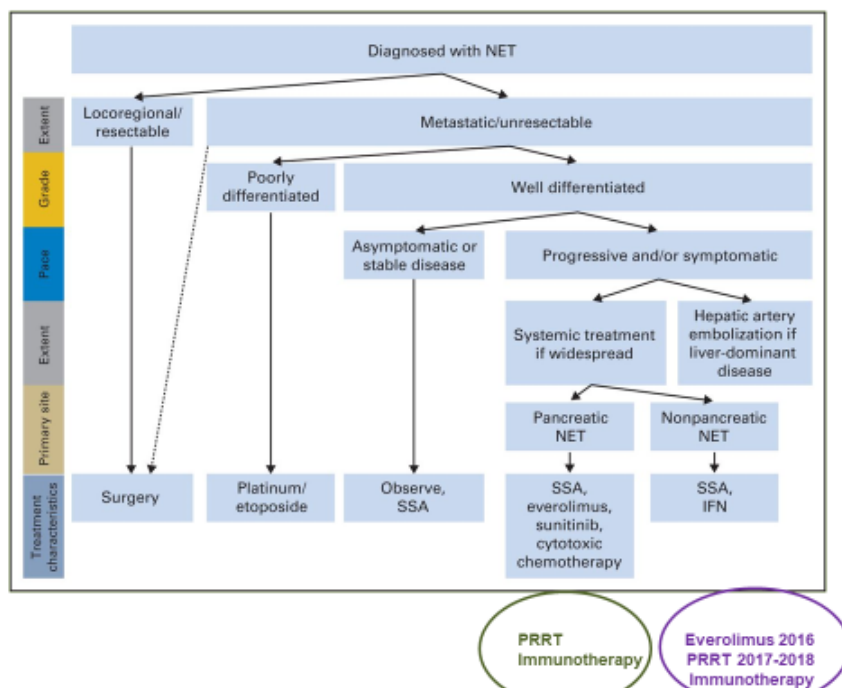
Treatment of patients with GEPNETs should be done by a multidisciplinary team of medical oncologists, surgical oncologists, interventional radiologists, nuclear medicine physicians and others. Complete surgical resection of early stage GEPNETs is the only curative option. The indications, extent and timing of surgical resection of advanced or metastatic disease are controversial. Most management guidelines suggest that surgery should be performed when 90% or higher of burden of disease is resectable²¹. This is possible in only 5 to 20% of patients²². Key clinical factors that are considered in the treatment decision-making of patients with GEPNETs include

- Extent of disease: does patient have resectable disease?
- Grade of tumor: Well differentiated vs poorly differentiated
- Burden of metastatic disease
- Pace of clinical course: rate of progression
- Presence and severity of symptoms
- Patient performance status, nutritional status
- Patient preference

An algorithm for the management of patients with GEPNETs²³ is shown in Figure 3

Figure 3

Algorithm for approaching tumor control in neuroendocrine tumors (NETs).



Kunz PL JCO 2015; 33: 1855-1863

Systemic Therapies for GEPNETs

In the current protocol I review the management of well differentiated GEPNETs. The treatment of metastatic poorly differentiated GEPNETs is beyond the scope of the protocol. The goals of systemic therapies for patients with metastatic GEPNETs are:

- Antineoplastic: Tumor control
- Treatment of symptoms: Control of neuroendocrine syndromes: carcinoid syndrome and others

Patients with metastatic well differentiated neuroendocrine tumors have an indolent clinical course. The primary end-point of prospective randomized clinical trials (RCT) evaluating the safety and efficacy of new systemic therapies for low grade GEPNETs is progression free survival (PFS). Secondary end points include objective response rates (ORR), overall survival (OS), evaluation of biomarkers and others. Level 1 evidence demonstrating safety and efficacy of anti-neoplastic systemic therapies for metastatic GEPNETs include:

- Long acting somatostatin analogues: octreotide LAR and lanreotide
- Mechanistic target of rapamycin (MTOR) inhibitors: everolimus
- Anti-vascular endothelial growth factor receptor (VRGFR)-tyrosine kinase inhibitors (TKIs): sunitinib - pancreatic neuroendocrine tumors only
- Peptide receptor radionuclide therapy (PRRT): ¹⁷⁷Lutetium-DOTA0-Tyr3-octreotate (177Lu-Dodadate)

Long acting somatostatin analogues (SSAs)

A phase III RCT of octreotide LAR 30 mg IM every four weeks in 85 patients with progressive metastatic low grade mid-gut neuroendocrine tumors showed a time to tumor progression (TTP) of 14.3 months in patients treated with octreotide compared to 6.0 months in patients treated with placebo (HR:0.34, 95% CI 0.20-0.59, $p < .001$)¹². The results of this trial did not change the FDA prescribing information (PI) label of octreotide LAR which is approved in the US for the symptomatic treatment of carcinoid syndrome. A phase III RCT of lanreotide 120 mg SQ every 4 weeks in patients with advanced non-functional pancreatic and non-pancreatic neuroendocrine tumors without evidence of progression at the time of enrollment showed a progression free survival (PFS) of 18.0 months in patients treated with placebo. PFS in patients treated with lanreotide was not reached at the time of the publication of this clinical trial (HR: 0.47, 95% CI 0.30-0.73, $p < .001$)¹³. Based on these results, the FDA approved lanreotide as an anti-neoplastic agent for patients with metastatic GEPNETs. In both clinical trials the toxicity of long acting somatostatin analogues was manageable. Common toxicities included bloating, constipation, diarrhea, steatorrhea, cholelithiasis and others. The above RCTs confirmed a class-effect of SSAs as systemic anti-neoplastic therapies for advanced GEPNETs. Currently, octreotide LAR 20 to 40 mg IM every 4 weeks or lanreotide 120 mg SQ every 4 weeks are widely used as a backbone frontline systemic therapy in patients with metastatic GEPNETs.

Mechanistic target of rapamycin (MTOR) inhibitors

A phase III RCT evaluating the safety and efficacy of the oral MTOR inhibitor everolimus 10 mg PO daily versus placebo in 410 patients with low or intermediate grade advanced or metastatic PNETs who had disease progression within 12 months prior to enrollment showed a PFS of 11.0 months in patients treated with everolimus compared to 4.6 months in patients treated with placebo (HR:0.35, 95% CI 0.27-0.45, $p < .001$)²⁴. Another phase III RCT of everolimus 10 mg PO daily versus placebo in 302 patients with metastatic low grade, non-functional neuroendocrine tumors of the mid-gut and lung who had disease progression within 12 months of enrollment showed a median PFS of months 11.0 in patients treated with everolimus compared to 3.9 months in patients who took placebo (HR: 0.48, 95% CI: 0.35-0.67, $p < .00001$)²⁵. Radiographic tumor response rates were low in both clinical trials. The toxicity of everolimus was manageable in both clinical trials. Some of the side effects of everolimus included hyperglycemia, hypertriglyceridemia, abnormalities of liver function tests, rare reports of pneumonitis and others. In 2011, the FDA approved everolimus as an anti-neoplastic agent for the treatment of adults with progressive unresectable, locally advanced or metastatic PNETs. In 2016, the FDA approved

everolimus for adults with progressive, unresectable, locally advanced or metastatic well differentiated, non-functional neuroendocrine tumors (NETs) of gastrointestinal or lung origin.

Vascular endothelial growth factor receptor (VEGFR)-tyrosine kinase inhibitors (TKIs)

A phase III RCT evaluating the safety and efficacy of the oral anti-VGFR TKI sunitinib 37.5 mg PO daily in 171 patients with advanced pancreatic neuroendocrine tumors (PNETs) with progression within 12 months prior to enrollment showed a PFS of months 11.4 months in patients treated with sunitinib²⁶ compared to 5.5 months in patients treated with placebo (HR: 0.42 95% CI 0.26-0.66, p<.001) (Raymond). Radiographic tumor response rates were low. Sunitinib was well tolerated. Reported adverse events included hypertension, proteinuria, hypothyroidism, fatigue and others. In 2011, the FDA approved sunitinib for the treatment of patients with progressive metastatic PNETs.

Cytotoxic chemotherapy

A proportion of PNETs are deficient in DNA repair mechanisms²⁷. That tumor characteristic makes them susceptible to DNA damage and cell death caused by alkylating agent-based combination cytotoxic chemotherapy. Small clinical trials in patients with advanced PNETs from the eighties and nineties showed that alkylating agent-based combination chemotherapy with streptozosyn was associated with improvements in PFS²⁸. Streptozosyn is approved by the FDA for treatment of advanced PNETs but it has largely been abandoned due to a severe toxicity profile. More recently, multiple phase II studies have demonstrated the safety and efficacy of oral alkylating agent-based combination chemotherapy with temozolomide for advanced PNETs²⁹. A combination of temozolomide plus the oral fluoropyrimidine capecitabine for patients with advanced PNETs is showing promising efficacy and safety outcomes. The rationale for a combination of temozolomide plus capecitabine includes:

- Temozolomide caused DNA damage through methylation of DNA resulting in cell death
- Capecitabine causes tumor depletion of the DNA repair gene MGMT
- Capecitabine increases chemo-sensitivity of PNETs to temozolomide
- Capecitabine plus temozolomide are synergistic and do not have overlapping toxicities
- Maximum synergy can be achieved with 9 days of daily single agent capecitabine followed by five days of a daily combination of temozolomide + capecitabine

Phase III RTCs are needed to confirm the safety and efficacy of temozolomide plus capecitabine for advanced PNETs. Currently, the role of temozolomide plus capecitabine for non-pancreatic neuroendocrine tumors is unknown and needs to be evaluated in well- designed phase III RCTs.

Peptide Receptor Radionuclide Therapy (PRRT)

PRRT is a form of targeted systemic radiotherapy for metastatic low grade neuroendocrine tumors (NETs). A majority of these tumor express somatostatin receptors and can be therapeutically targeted with radiolabeled somatostatin analogues. PRRT is based on the intravenous administration of radiolabeled somatostatin analogues allowing the delivery of radionuclides directly to neuroendocrine tumor cells. The most promising radiolabeled somatostatin analogue is ¹⁷⁷Lutetium-DOTA⁰-Tyr³-octreotate (¹⁷⁷Lu-Dodadate). The radionuclide ¹⁷⁷Lu is a beta and gamma emitter with a maximum particle range of 2 mm and a half-life of 160 hours. The prospective, randomized, phase 3 clinical trial Neuroendocrine Tumors Therapy (NETTER-1) demonstrated the safety, efficacy and superiority of ¹⁷⁷Lu-Dodadate compared to high dose octreotide in patients with advanced and metastatic mid-gut NETs who had disease progression on somatostatin analogue therapy³⁰. In NETTER-1, patients assigned to ¹⁷⁷Lu-Dodadate had a significant prolongation in progression-free survival (PFS), the primary end-point

of the trial. In addition, ¹⁷⁷Lu-Dodadate was associated with significant improvements in secondary endpoints like objective response rate (ORR) and overall survival (OS) compared to high dose octreotide-LAR. ¹⁷⁷Lu-Dodadate was well tolerated and was not associated with increase in renal adverse events. It is expected that the FDA will approve ¹⁷⁷Lu-Dodadate as second line treatment for patients with advanced or metastatic low grade mid-gut NETs with disease progression after somatostatin analogue therapy.

PRRT at UTSW Medical Center

An expanded access clinical trial of ¹⁷⁷Lu-Dodadate for patients with metastatic low-grade NETs with disease progression after long acting somatostatin analogue therapy is available at UTSW Medical Center. The lead investigator for this trial is Dr. Rathan Subramanian from nuclear medicine. This trial allows our patients access to PRRT and enhances our multidisciplinary service for patients with GEPNETs.

Carcinoid Syndrome

Carcinoid syndrome is caused by excess hormone and bioactive neuroamine secretion by functional GEPNETs³¹. Excess secretion of serotonin by the malignant neuroendocrine cell plays a central role in the manifestations of this syndrome.

Carcinoid syndrome develops in 1.7-18.4% of patients with neuroendocrine tumors. Between 60-78% of patients with carcinoid syndrome have metastatic mid-gut neuroendocrine tumors. In 91% of cases liver metastases are predominant. Carcinoid syndrome without liver metastases can develop in the following settings:

- Metastatic bulky retroperitoneal lymphadenopathy
- Lung neuroendocrine tumors
- Ovarian neuroendocrine tumors

Common symptoms of carcinoid syndrome include:

- Sudden flushing
- Skin pruritus
- Feeling of warmth
- Lacrimation
- Facial or conjunctival edema
- Palpitations
- Wheezing and bronchospasm in lung neuroendocrine tumors
- Diarrhea

Below are some of the common chronic complications and end organ damage that can result from untreated carcinoid syndrome:

- Myopathy
- Pellagra like skin disease – niacin (vitamin B3) deficiency. L-tryptophan is diverted to excess serotonin production. Since L-tryptophan plays a central role in niacin metabolism, a deficiency of niacin develops.
- Arthropathy
- Cyanosis in bronchial carcinoid

- Telangiectasia
- Mesenteric fibrosis
- Carcinoid heart disease: right endocardial fibrosis

Treatment of Chronic Diarrhea Refractory to Somatostatin Analogue Therapy in Carcinoid Syndrome

A comprehensive review of the treatment of carcinoid syndrome is beyond the scope of the current protocol. The reader is directed to the consensus guidelines for surveillance and medical management of midgut neuroendocrine tumors published earlier this year by the North American Neuroendocrine Tumor Society (NANETS)³².

As a summary, lifestyle changes including diet modifications and avoidance of stress play an important role in the symptomatic control of carcinoid syndrome. For patients with niacin deficiency replacement with oral nicotinamide is indicated. Control of chronic diarrhea caused by excess production of serotonin can be a challenging clinical scenario in patients with functional neuroendocrine tumors. Treatment options for chronic diarrhea include:

- Short acting and sustained release somatostatin analogues
- Loperamide
- Diphenoxylate
- 5-HT₃ receptor antagonists: ondansetron
- H₁ and H₂ receptor blockers (gastric NET)
- Regional therapy of hepatic metastases like hepatic arterial bland embolization
- Peripheral inhibition of serotonin synthesis in the GI tract: telotristat ethyl

Telotristat Ethyl a New Treatment Option for Diarrhea in Patients with Carcinoid Syndrome

In patients with carcinoid syndrome, uncontrolled diarrhea defined as four or more bowel movements (BM) per day despite stable somatostatin analogue therapy is common and represents a challenging clinical scenario. Peripheral inhibition of serotonin synthesis in the GI tract by the oral inhibitor of tryptophan hydroxylase telotristat ethyl is a new treatment option for these patients³³. The safety and efficacy of telotristat in patients with carcinoid syndrome diarrhea refractory to somatostatin analogue therapy was demonstrated in a well-designed, randomized, double blind, placebo controlled, parallel arm phase III clinical trial³⁴. In this study, treatment with telotristat resulted in a significant reduction of BM and significant decrease of 5-hydroxyindolacetic acid (5-HIAA) in 24-hour urine. Based on the result of this study, the FDA approved telotristat 250 mg per mouth three times a day with food for the treatment of carcinoid syndrome diarrhea in combination with somatostatin analog (SSA) therapy in adults inadequately controlled by SSA therapy. Now, it is unknown if telotristat has antineoplastic effects in patients with GEPNETs.

VII.SUMMARY: CURRENT CONCEPTS IN GEPNETs

As we finish 2017, we have a better knowledge of the epidemiology, classification, pathophysiology, clinical course, diagnostic evaluation, treatment and prognosis of patients with neuroendocrine tumors²³. Current concepts that enhance our understanding of these malignancies include:

- A classification of neuroendocrine tumors considering the site of the primary tumor: pancreatic versus non-pancreatic (mid-gut/lung) and tumor grade: well differentiated versus poorly differentiated is crucial in patient management and in clinical trial design.

- Most patients with neuroendocrine tumors have an indolent clinical course, therefore progression free survival (PFS) is a primary efficacy end-point in clinical trials evaluating new therapies for this patient population
- Multiple treatment options are now available in the clinic for patients with advanced and metastatic neuroendocrine tumors. Choice of treatment is complex and ideally should result from a multidisciplinary evaluation of the patient.
- Treatment choice is made based on key clinical factors:
 - Primary tumor site
 - Tumor grade
 - Extent of disease
 - Rate of progression
 - Functional status of tumor: carcinoid syndrome, other endocrine syndromes
 - Specific treatment factors: efficacy, safety, cost
 - Patient preference

VIII.THE FUTURE: PRIORITIES IN MANAGEMENT AND CLINICAL RESEARCH IN GEPNETs

Priorities to advance our understanding and management of patients with neuroendocrine tumor include:

- Improving the histologic classification of neuroendocrine tumors
- Developing molecular profiling/classification of neuroendocrine tumors
- Discovery of new prognostic and predictive factors
- Development of new functional imaging studies: positron emission tomography (PET)-based studies
- Develop validated criteria for radiographic and functional evaluation of response of tumors to systemic therapy
- Evaluating the safety and efficacy of combination systemic therapy like peptide receptor radionuclide therapy (PRRT) plus immunotherapy
- Prospective assessment of quality of life, patient reported outcomes, survivorship and cost-effectiveness analysis of treatment in clinical trials

REFERENCES

1. Yao JC, Hassan M, Phan A, et al. One hundred years after “carcinoid”: Epidemiology of and prognostic factors for neuroendocrine tumors in 35,825 cases in the United States. *J Clin Oncol* 2008; 26:3063-3072.
2. Lubarsch O. Ueber dem primären Krebs des Ileum nebst Bemerkungen b“er das gleichzeitige Vorkommen von Krebs und Tuberculose. *Virchows Arch Pathol Anat* 1888; 111: 280 –317
3. Obendorfer S. Karzinoide tumoren des dunndarms. *Frankf Zschr Pathol* 1907; 1: 426–430.
4. Dasari A, Shen C, Halperin D, et al. Trends in the incidence, prevalence, and survival outcomes in patients with neuroendocrine tumors in the United States. *JAMA Oncol* 2017 Oct 3(10): 1335-1342
5. Bosman FT, Carneiro F, Hruban RH, et al:(eds). *WHO Classification of Tumours of the Digestive System* (ed 4). Lyon, France, International Agency for Research on Cancer, 2010

6. Travis W. The concept of pulmonary neuroendocrine tumours. Pathology and Genetics of Tumours of the Lung, Pleura, Thymus and Heart. Lyon, France, International Agency for Research on Cancer Press, 2004
7. Brazeau P, Vale W, Burgus R, et al. Hypothalamic polypeptide that inhibits the secretion of immunoreactive pituitary growth hormone. Science 1973; 179: 77–79.
8. Reubi JC, Waser B, Schaer JC, et al. Somatostatin receptor sst1–sst5 expression in normal and neoplastic human tissues using receptor autoradiography with subtype-selective ligands. Eur J Nucl Med 2001; 28: 836–846.
9. Wängberg B, Nilsson O, Johanson L, et al. Somatostatin receptors in the diagnosis and therapy of neuroendocrine tumors. The Oncologist 1997; 2:50-58
10. Buscail L, Delesque N, Esttve JP, et al. Stimulation of tyrosine phosphatase and inhibition of cell proliferation by somatostatin analogues: mediation by human somatostatin receptor subtypes SSTR1 and SSTR2 (somatostatin analogue RC-160/SMS-201-5/deased ce growth/cancer). roc. Nati. Acad. Sci. USA March 1994. Vol. 91: 2315-2319.
11. Longo DL, Fauci AS, Dennis. Kasper DL, Hauser SL, Jameson JL, Loscalzo J. Harrison's Principles of Internal Medicine, 18th Edition 2012. The McGraw- Hill Companies, Inc.
12. Rinke A, Müller HH, Schade-Brittinger C, et al. Placebo-controlled, double-blind, prospective, randomized study on the effect of octreotide LAR in the control of tumor growth in patients with metastatic neuroendocrine midgut tumors: a report from the PROMID Study Group. J Clin Oncol. 2009 Oct 1;27(28):4656-63.
13. Caplin ME, Pavel M, Ćwikła JB, et al. Lanreotide in metastatic enteropancreatic neuroendocrine tumors. N Engl J Med. 2014 Jul 17;371(3):224-33
14. O'Dorisio TM, Phan AT, Langdon RM, et al. Relief of bowel-related symptoms with telotristat etiprate in octreotide refractory carcinoid syndrome: Preliminary results of a placebo-controlled, multicenter study. J Clin Oncol 2012. Abstract 312
15. Francis JM, Kiezun A, Ramos AH, et al. Somatic mutation of CDKN1B in small intestine neuroendocrine tumors. Nat Genet 2013; 45:1483-1486
16. Jiao Y, Shi C, Edil BH, et al. DAXX/ATRX, MEN1, and mTOR pathway genes are frequently altered in pancreatic neuroendocrine tumors. Science 2011; 331:1199-1203.
17. Raoof M, Jutric Z, Melstrom LG, et al. Prognostic significance of chromogranin A in small pancreatic neuroendocrine tumors. J Clin Oncol 2017. Abstract 375
18. Reubi JC, Kvols L, Krenning E, et al. Distribution of somatostatin receptors in normal and tumor tissue. Metabolism 1990 39:78-81 (suppl 2)
19. Rufini V, Calcagni ML, Baum RP. Imaging of neuroendocrine tumors. Semin Nucl Med 2006 36: 228-247.
20. Sadowski SM, Neychev V, Millo C, et al. Prospective study of ⁶⁸Ga-DOTATATE positron emission tomography/computed tomography for detecting gastro-entero-pancreatic neuroendocrine tumors and unknown primary sites. J Clin Oncol 2016 February; 34(6): 588-599.

21. Plockinger U, Rindi G, Arnold R, et al. European Neuroendocrine Tumour Society: Guidelines for the diagnosis and treatment of neuroendocrine gastrointestinal tumours: A consensus statement on behalf of the European Neuroendocrine Tumour Society (ENETS). *Neuroendocrinology* 2004; 80:394-424.
22. Saxena A, Chua TC, Perera M, et al. Surgical resection of hepatic metastases from neuroendocrine neoplasms: A systematic review. *Surg Oncol* 2012; 21: e131-e141.
23. Kunz PL. Carcinoid and Neuroendocrine Tumors: Building on Success. *J Clin Oncol* 2015 June; 33(16): 1855-1864
24. Yao JC, Shah MH, Ito T, et al. Everolimus for advanced pancreatic neuroendocrine tumors. *N Engl J Med* 2011 364:514-523.
25. Yao JC, Fazio N, Singh S, et al. Everolimus for the treatment of advanced, non-functional neuroendocrine tumours of the lung or gastrointestinal tract (RADIANT-4): a randomised, placebo-controlled, phase 3 study. *Lancet* 2016 Mar 5;387(10022):968-977
26. Raymond E, Dahan L, Raoul JL, et al. Sunitinib malate for the treatment of pancreatic neuroendocrine tumors. *N Engl J Med* 2011 364:501-513.
27. Liu IH, Ford JM, Kunz PL. DNA-repair defects in pancreatic neuroendocrine tumors and potential clinical applications. *Cancer Treat Rev* 2016 Mar; 44: 1-9
28. Moertel CG, Lefkopoulo M, Lipsitz S, et al. Streptozocin–Doxorubicin, Streptozocin–Fluorouracil, or Chlorozotocin in the Treatment of Advanced Islet-Cell Carcinoma. *N Engl J Med* February 1992; 326: 519-523.
29. Kotteas EA, Syrigos KN, Wasif Saif M. Profile of capecitabine/temozolomide combination in the treatment of well-differentiated neuroendocrine tumors. *Onco Targets Ther* 2016; 9:669-704
30. Strosberg J, El-Haddad G., Wolin E, et al. Phase 3 Trial of ¹⁷⁷Lu-Dotate for midgut neuroendocrine tumors. *N Engl J Med* 2017 Jan; 376(2); 125-135.
31. Kulke MH. Advances in the management of patients with carcinoid syndrome. *Clin Adv Hematol Oncol*. 2017 Apr;15(4):257-259.
32. Strosberg JR, Halfdanarson TR, Bellizzi AM, et al. The North American Neuroendocrine Tumor Society Consensus Guidelines for Surveillance and Medical Management of Midgut Neuroendocrine Tumors. *Pancreas*. 2017 Jul;46(6):707-714
33. Wiedenmann B, Pavel ME, Seufferlein T, et al. The effect of telotristat etiprate on clinical and biochemical responses in patients with symptomatic carcinoid syndrome: Preliminary results of an ongoing phase II, multicenter, open-label, serial-ascending dose study. *J Clin Oncol* 2012 May. Abstract e 14564
34. Kulke MH, Hörsch D, Caplin ME, et al. Telotristat Ethyl, a Tryptophan Hydroxylase Inhibitor for the Treatment of Carcinoid Syndrome. *J Clin Oncol* Jan 2017; 35 (1): 14-23.