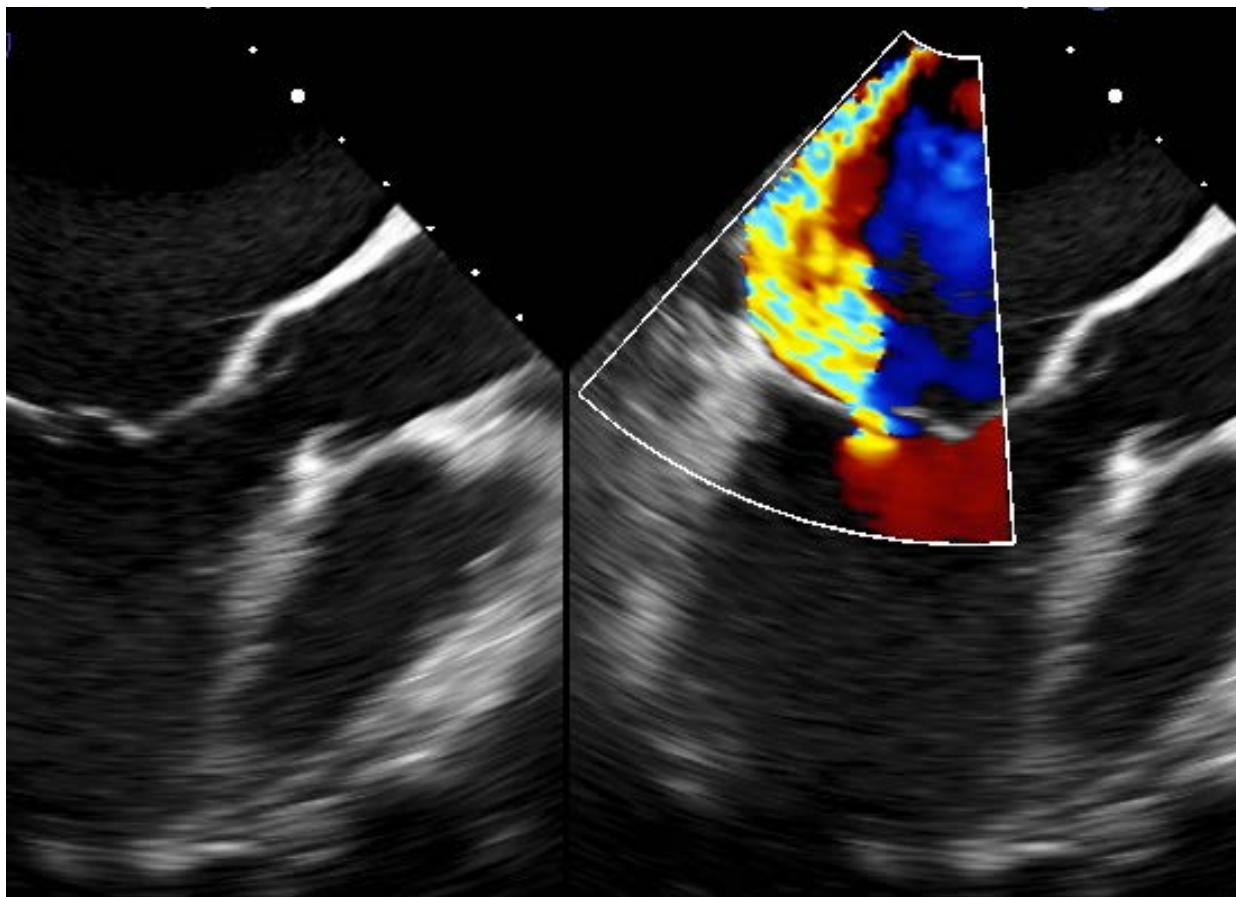

Treating Mitral Regurgitation in 2017

Michael Luna, MD
UT Southwestern Medical Center
March 10, 2017

This is to acknowledge that Michael Luna, M.D. has disclosed that he does not have any financial interests or other relationships with commercial concerns related directly or indirectly to this program. Dr. Luna will not be discussing off-label uses in his presentation.

Michael Luna, M.D., F.A.C.C., F.S.C.A.I.
Assistant Professor of Medicine
Division of Cardiology
Interventional Cardiology
UT Southwestern Medical Center/Parkland Memorial Hospital

Dr. Luna earned his B.S., summa cum laude, in Biology from the University of Texas-Pan American and his M.D. from the University of Texas Southwestern Medical Center. He stayed on at UT Southwestern and completed his internship/residency in Internal Medicine as well as General and Adult Interventional Cardiology fellowships, during which time he also trained in Adult Congenital Heart Disease. He then completed a fellowship in Pediatric Interventional Cardiology at Children’s Medical Center here in Dallas prior to joining the faculty in the Division of Cardiology here at UT Southwestern Medical Center. Dr. Luna’s primary interest is in transcatheter therapies for advanced cardiac pathology and is clinically active on multiple fronts in this respect; these include coronary chronic total occlusions, advanced structural heart disease, and adult congenital heart disease.

Purpose and Objectives: The purpose of this presentation is to discuss mitral regurgitation (MR). Although the effects of mitral regurgitation follow a single physiologic pathway, the mechanism of this lesion can vary and can have implications on the treatment modality and on the long term prognosis of the patient. By the end of this presentation, the listener should have a better understanding of (a) the prevalence of this valvular lesion, (b) its pathophysiology, (c) its long term prognosis, and (d) current and emerging treatment modalities.

Valvular heart disease is one of the major forms of structural heart disease, and among all valvular lesions, mitral regurgitation is one of the most prevalent; in fact, it is more common than both aortic stenosis and aortic insufficiency¹⁻³. It is second only to tricuspid regurgitation. In a population of patients presenting for heart failure evaluation, approximately 50% were found to have a mild or moderate valvular lesion; however, only approximately 3% of them had a severe lesion¹. It is this smaller segment of the population that will have a significant clinical impact from their valvular heart disease and will require some form of intervention to

circumvent the patient's demise. It is clear that age plays an important role on incident valvular heart disease with the highest risk existing in patients that are older than 75³. Incident MR also increases with age, and with age come other medical co-morbidities that, many times, lead to inadequate treatment of this lesion.

Determining the mechanism of mitral regurgitation in every case is critical as this drives the management pathway that will be pursued. Mitral regurgitation is categorized as either **primary** or **secondary**. When the primary inciting pathology involves the valve or subvalve apparatus itself, mitral regurgitation is considered primary; it is also referred to as organic or degenerative⁴. Secondary MR, on the other hand, is related primarily to pathology of the left ventricular myocardium and is also referred to as functional⁵. The etiologies of primary MR include valve prolapse/flail (fibroelastic deficiency, Barlow's disease), rheumatic heart disease, endocarditis (infective or non-infective), inflammatory diseases (collagen vascular diseases), radiation-induced, and congenital heart disease (cleft mitral valve in atrioventricular septal defects). Many of these degenerative valve processes can lead to valve prolapse/flail, usually involving prolapse of an isolated segment but can also involve multiple segments.

Mitral valve prolapse is the most common etiology of primary MR in the developed world. Younger patients tend to present with Barlow's disease and older patients with fibroelastic deficiency disease (FED)⁶ (Figure 1). Barlow's disease is marked by severe myxoid degeneration that leads to voluminous thickening and gross redundancy of both anterior and posterior leaflets of the mitral valve⁷. Elongation and thickening or thinning of the chordal apparatus is also present; this pathology can lead to sudden chordal rupture and, thus, acute on chronic MR.

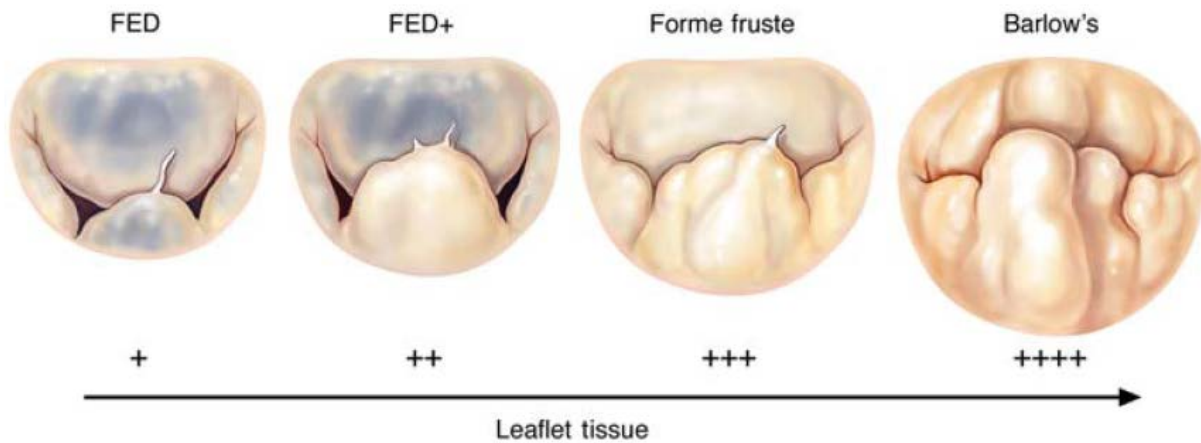


Figure 1. Spectrum of primary MR pathology that can present as prolapse/flail. From reference 1.

The normal three-layer architecture of the mitral valve is disrupted in Barlow's disease^{8,9}. This is in contrast to FED where the normal leaflet architecture is maintained. In FED, instead of there being an excess in connective tissue, there is a deficiency in it; this leads to thinning of leaflet and chordal tissue and eventually chordal rupture. The etiology of deficiency in collagen, elastins, and proteoglycans that is seen in these patients is unknown but it is thought age may play a role¹⁰.

Because secondary MR is a left ventricular myocardial disease process, the mitral valve apparatus should be normal. This type of MR is also further characterized as ischemic versus non-ischemic and is commonly present patients with cardiomyopathy¹¹. Moderate to severe MR can be present in up to 50% of patients with left ventricular systolic dysfunction¹². Secondary MR tends to be very dynamic and the degree of insufficiency can be very dependent on left ventricular loading conditions. Exercise can also significantly change the degree of regurgitation, even increasing from mild to severe in certain instances^{13,14}. Although ischemic and non-ischemic MR are both considered secondary forms of MR their pathologies at the myocardial level can be very different¹⁵. Even ischemic MR, caused by coronary artery disease with myocardial infarction, can have different mechanisms of MR based on where the myocardial scar is located. What is shared by all forms of secondary MR is the general pathophysiology of it: a disequilibrium between forces on the valve that normally keep it closed during contraction of the ventricle. The mitral valve apparatus is intricate and is

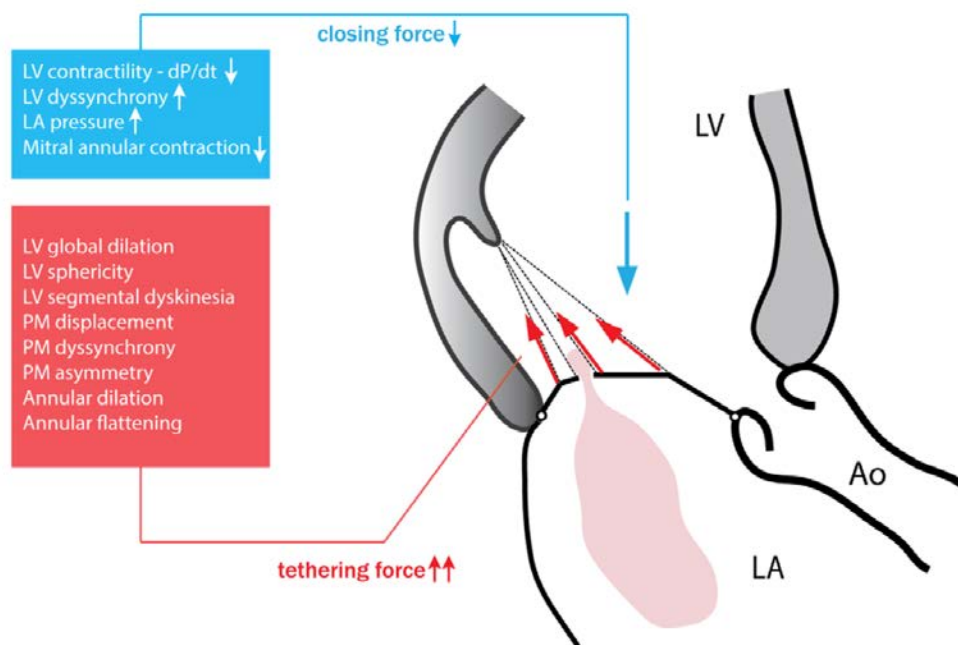


Figure 2. Imbalance in opposing forces that act on the mitral valve, leading to MR. From reference 15.

composed of an annulus, a valve (anterior and posterior leaflets), and the subvalve apparatus (chordae tendineae and anterolateral/posteromedial papillary muscles); the adjacent left ventricular wall can also be considered part of the valve apparatus. There are normally two valve forces that have very close interplay with each other, culminating in adequate closure of the mitral valve: (1) closing forces and (2) tethering forces¹⁵. The major closing force applied on the mitral valve comes from the contracting left ventricle but mitral annular contraction and left ventricular synchrony also contribute. Tethering forces counter the effects of these closing forces so as to maintain adequate closure of the mitral valve. Disruption in the balance between these two forces leads to inadequate leaflet coaptation and, thus, mitral regurgitation (Figure 2).

The acuity and degree of MR dictates how acute and profound the patient's clinical presentation is. Although this discussion is focusing on chronic MR, it is worth briefly discussing acute MR. Acute MR patients usually have very sudden cardiopulmonary deterioration; the three most common causes of acute MR are myocardial infarction, chordal rupture in the setting of underlying myxomatous disease, and leaflet perforation from infective endocarditis¹⁶. These patients will present with hypotension, tachycardia, and pulmonary edema but will be found to have normal left heart chamber dimensions (Figure 3). Left atrial pressures will be significantly elevated and V waves, if measured invasively, will be particularly prominent;

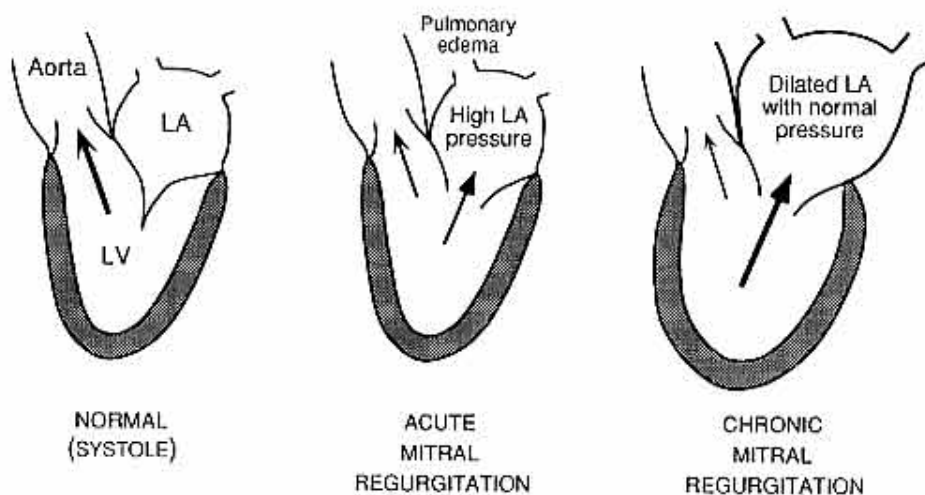


Figure 3 Effects of acute versus chronic MR. From www.brown.edu.

because of this marked elevation in left atrial pressure, the prominent systolic murmur that is present in chronic MR is commonly not that impressive in acute MR. It is important to mention that these mechanisms of acute MR may initially cause a degree of MR that is not severe

enough to manifest itself clinically; the regurgitation in these patients tends to progress over time leading to compensatory eccentric hypertrophy of the left ventricle. Their clinical presentation often occurs much later from the time of original injury. These patients are then considered to have chronic MR and will present clinically like most other chronic MR patients will: with congestive heart failure, arrhythmias, or rarely with sudden death; although, limited exercise tolerance may be the first sign¹⁷.

For chronic primary MR, once the regurgitant lesion begins to pose a volume load on the left ventricle and atrium, a cascade of pathologic changes begins that culminates in a variety of clinical presentations. As previously mentioned, mild exercise intolerance is the most common presentation; however, the patient may present with congestive heart failure and concomitant arrhythmias, especially atrial fibrillation, which can be the source of decompensation. The mainstay of treatment for severe symptomatic MR remains surgery, even in a patient with a left ventricular ejection fraction (LVEF) $\leq 30\%$. For the asymptomatic patient, there are two major considerations: (1) if the LVEF is $\leq 60\%$ and the left ventricular end-systolic dimension (LVESD) is ≥ 40 mm then valve surgery, either with repair or replacement, is recommended; (2) and if the valve anatomy is felt to be *repairable*, with 95% certainty and with a predicted $< 1\%$ surgical mortality by a cardiac surgeon, then surgery is recommended if (a) atrial fibrillation or pulmonary hypertension with a pulmonary artery systolic pressure of > 50 mmHg is present and (b) despite an LVEF $> 60\%$ and LVESD < 40 mm¹⁸.

The mechanism of mitral regurgitation has implications on overall prognosis. In primary MR, the MR itself is the disease and in secondary MR, the MR is a consequence of the disease. Thus, removal of MR in the primary variety is considered curative, but what effect removal of MR has in the secondary form remains a point of debate. Certainly, it is clear that increased mortality tracks with the degree of secondary MR present in patients with cardiomyopathy¹⁹. What remains unclear is whether the MR in these patients is a true target for therapy or simply a marker of a *sicker* heart with overall outcomes being driven entirely by the underlying cardiomyopathy itself. What further complicates the field of secondary MR is the *lumping together* of both ischemic and non-ischemic varieties under the same umbrella. The most common surgical strategy is a repair with undersized ring annuloplasty; however, this alone may not be adequate, and this intervention could biologically act differently between ischemic and non-ischemic MR where the papillary muscle and general ventricular changes can be very

different¹⁵. Multiple studies have consistently shown, at midterm follow-up, a recurrence rate of MR >2+ following restrictive annuloplasty in the range of 30%; however, one study even reported a close to 60% recurrence risk of moderate or severe MR at 2 years²⁰. Given the subvalvular alterations that can occur with secondary MR, some believe that an addition of papillary muscle approximation to ring annuloplasty is required to achieve a more durable result²¹. So, where does the benefit truly lie? Is it in a *durable* reduction of MR, or in ventricular geometric alteration. . . or both. . . or neither? If the answer lied solely in the reduction in MR then, theoretically, replacing the mitral valve with a prosthesis leading to removal of MR completely would prove to be the best strategy. However, this has not been the case. In a randomized control trial comparing mitral valve repair to chordal-sparing valve replacement in ischemic MR, although valve replacement performed much better in MR reduction, it did not correlate with better long term outcomes, including death²². Given this, as of yet, unconvincing data regarding the benefit of surgical treatments of secondary MR, the current guidelines give a IIb recommendation for surgical treatment only in patients with severe secondary MR with residual New York Heart Association class III-IV symptoms *only after* medical therapy and cardiac resynchronization therapy have been attempted¹⁸.

Because of the unclear benefit in surgically addressing secondary MR, many patients, even those with refractory heart failure, are still not offered surgical mitral therapies. Even in primary MR, where the benefits of MR reduction are clear, many patients are not offered surgery²³. If you look at all-comers with MR, there are many reasons that lead to the decision not to offer surgery: (1) left ventricular systolic dysfunction, (2) non-ischemic etiology, (3) older age, (4) comorbidities, and (5) grade 3+ MR versus 4+²⁴. Frailty and severe pulmonary hypertension, especially with associated right heart disease, are also known contributors. Pulmonary hypertension can be a complication of long standing severe MR; those with reversible pulmonary pressures are thought to do well with surgical treatment of MR but those with fixed pulmonary hypertension have very poor outcomes and are usually turned down for surgery²⁵.

From this, the many real world reasons surgery is not offered to patients with severe MR, the field of transcatheter therapies was born. Although many transcatheter repair therapies have been conceived including coronary sinus-based devices, direct suture annuloplasty devices, and even left ventricular geometric alteration devices, the one device that has truly come to fruition and has made an impact in the field is MitraClip® (Abbott Vascular, Menlo Park, CA). The basic concept of this device originated in the surgical realm, by Dr. Alfieri, a cardiac surgeon who described the

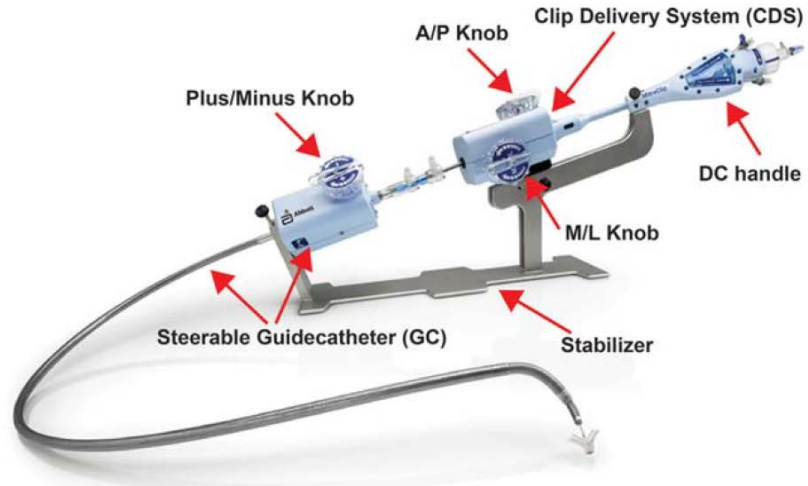


Figure 4. MitraClip® System. From Abbott Vascular.

surgical repair of single or bileaflet mitral valve prolapse²⁶. His technique consisted of the application of suture to the free edge of the prolapsed leaflet and to the corresponding edge of the opposite leaflet, effectively anchoring the two leaflets together and creating a double orifice valve. While good outcomes were described on his original publication the technique was not widely used. The MitraClip® system is an intricate device consisting of two main steering components: (1) a steerable guide catheter and (2) a clip delivery system (Figure 4). The system is introduced via the femoral vein into the left atrium through a transseptal

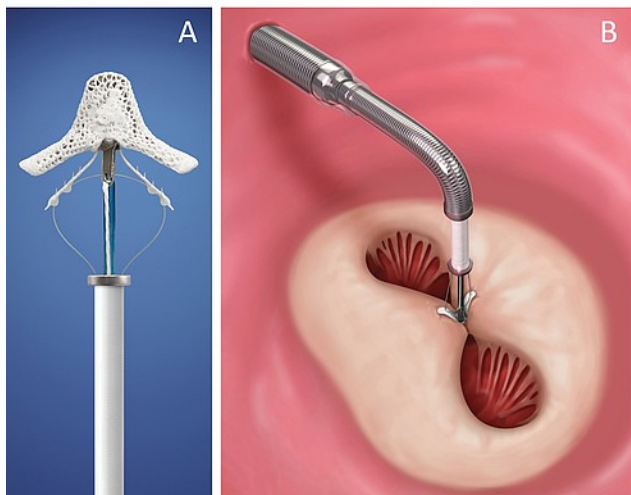


Figure 5. (A) MitraClip® in open position with exposed grippers. (B) MitraClip® deployed with resultant double orifice. From Abbott Vascular.

puncture; the system allows delivery of a cobalt chromium clip that has a polyester covering to promote tissue growth. The delivery system allows the clip to be delivered in a beating heart using transesophageal echocardiographic and fluoroscopic guidance and positioned along the culprit leaflet segments; when closed with leaflet tissue grasped within it, the Alfieri edge-to-edge repair is replicated (Figure 5).

The EVEREST II trial was the pivotal trial that led to approval of the MitraClip® system. This study showed that a surgical approach to MR remained overall better at reducing MR but that MitraClip® implantation was a safer procedure compared to surgery. Five-year follow-up has now been reported. There was clearly a higher early need for mitral valve surgery in the MitraClip® group compared to the surgical group; however, when a landmark analysis was performed at 6 months, there was no further difference in rates of mitral valve re-operation between the two groups. Most importantly, the MitraClip® group incurred no survival penalty despite having higher early rates of a subsequent mitral valve operation. Furthermore, there was no decrement in left ventricular systolic function and the reduction in symptoms and left ventricular dimensions persisted out to 5 years²⁷. These data led to FDA approval for use of MitraClip® in patients with primary MR that are considered to carry a prohibitive surgical risk. The use of MitraClip® in secondary MR is currently being studied in the COAPT trial.

Although MitraClip® has played and continues to play an important role in filling the large gap of patients that are not offered surgical therapies for MR, the therapy has its limitations, especially in patients with severe Barlow's disease, those with large flail gap heights, and those with a significant concomitant degree of functional mitral stenosis. Transcatheter mitral valve replacement (TMVR) has now been introduced as a contender in this space. The experience that has accumulated worldwide with transcatheter valve implantations in the aortic and pulmonic positions made transition to the mitral position quick; however, the much more complex anatomy of the mitral valve has made engineering of TMVR systems a much more challenging feat. The mitral valve annulus is a much more sophisticated structure compared to that of the semilunar valves; it has a nonplanar, "D" and saddle-shaped construct with anterior and posterior peaks that are ~5 mm taller than the more apically-displaced medial and lateral insertions. The shape of the annulus is also more affected by ventricular systole. Also, the chordae tendineae complicate potential TMVR delivery mechanisms. There is an added risk of compromising surrounding cardiac structures with TMVR: (1) the left circumflex artery, (2) the aortic valve, (3) the conduction system, and (4) the LVOT, from anterior mitral leaflet displacement leading to outflow tract obstruction²⁸. Different from the diastolic pressure that is exerted on the closed aortic valve, the force being exerted on the closed mitral valve is the left ventricular systolic pressure. Because of this and the usual lack of calcification in most MR pathology, the anchoring mechanism of the TMVR system must not rely solely on radial force. There are many valves being tested, none of them currently approved for market use. However, early outcomes from one of the TMVR systems was recently reported, the Tendyne

Valve (Tendyne Holdings, LLC, a subsidiary of Abbott Vascular, Roseville, Minnesota) (Figure 6). Thirty patients with MR (23 with secondary MR) were treated with TMVR using the Tendyne Valve; the device was successfully implanted in 28 of the patients (93.3%). No acute deaths, strokes, or myocardial infarctions occurred. Prosthetic leaflet thrombosis was detected and successfully treated with anticoagulation in one patient. One patient died from hospital-acquired pneumonia 13 days following successful TMVR. At 30 days, mild central MR was present in one patient with the remaining 26 patients having no MR, and 75% of the patients reported no or mild residual symptoms at that follow-up. Long term follow-up has yet to be reported on these devices.




Figure 6. Tendyne Valve. From Tendyne Holdings, LLC, a subsidiary of Abbott Vascular.

Take Home Messages

1. Mitral regurgitation is a very common disease.
2. The etiology of MR is critical as it dictates the management strategy.
3. In primary MR, the MR itself is the disease and in secondary MR, the MR is a consequence of the disease.
4. Surgical therapies remain the gold standard for severe primary MR, and this can be a curative therapy.
5. Surgical therapies for secondary MR are reserved for residual symptoms after medical therapy has been optimized.
6. A large segment of the population with severe MR is not offered surgery for a variety of reasons.
7. Emerging transcatheter therapies may be the answer to patients who are deemed not good surgical candidates.
8. Once TMVR technology has been refined, it may provide an opportunity to adequately study, in a randomized fashion, the benefit of secondary MR compared to medical therapy.

References

1. Marciniak A, Glover K, Sharma R. Cohort profile: Prevalence of valvular heart disease in community patients with suspected heart failure in uk. *BMJ open*. 2017;7:e012240
2. Lloyd-Jones D, Adams RJ, Brown TM, Carnethon M, Dai S, De Simone G, Ferguson TB, Ford E, Furie K, Gillespie C, Go A, Greenlund K, Haase N, Hailpern S, Ho PM, Howard V, Kissela B, Kittner S, Lackland D, Lisabeth L, Marelli A, McDermott MM, Meigs J, Mozaffarian D, Mussolino M, Nichol G, Roger VL, Rosamond W, Sacco R, Sorlie P, Roger VL, Thom T, Wasserthiel-Smoller S, Wong ND, Wylie-Rosett J. Heart disease and stroke statistics--2010 update: A report from the american heart association. *Circulation*. 2010;121:e46-e215
3. Nkomo VT, Gardin JM, Skelton TN, Gottdiener JS, Scott CG, Enriquez-Sarano M. Burden of valvular heart diseases: A population-based study. *Lancet (London, England)*. 2006;368:1005-1011
4. Adams DH, Rosenhek R, Falk V. Degenerative mitral valve regurgitation: Best practice revolution. *European heart journal*. 2010;31:1958-1966
5. Patel JB, Borgeson DD, Barnes ME, Rihal CS, Daly RC, Redfield MM. Mitral regurgitation in patients with advanced systolic heart failure. *Journal of cardiac failure*. 2004;10:285-291
6. Anyanwu AC, Adams DH. Etiologic classification of degenerative mitral valve disease: Barlow's disease and fibroelastic deficiency. *Seminars in thoracic and cardiovascular surgery*. 2007;19:90-96
7. Trent JK, Adelman AG, Wigle ED, Silver MD. Morphology of a prolapsed posterior mitral valve leaflet. *American heart journal*. 1970;79:539-543
8. Misfeld M, Sievers H-H. Heart valve macro- and microstructure. *Philosophical Transactions of the Royal Society B: Biological Sciences*. 2007;362:1421-1436
9. Melnitchouk SI, Seeburger J, Kaeding AF, Misfeld M, Mohr FW, Borger MA. Barlow's mitral valve disease: Results of conventional and minimally invasive repair approaches. *Annals of Cardiothoracic Surgery*. 2013;2:768-773
10. Fornes P, Heudes D, Fuzellier JF, Tixier D, Bruneval P, Carpentier A. Correlation between clinical and histologic patterns of degenerative mitral valve insufficiency: A histomorphometric study of 130 excised segments. *Cardiovascular pathology : the official journal of the Society for Cardiovascular Pathology*. 1999;8:81-92
11. Yiu SF, Enriquez-Sarano M, Tribouilloy C, Seward JB, Tajik AJ. Determinants of the degree of functional mitral regurgitation in patients with systolic left ventricular dysfunction: A quantitative clinical study. *Circulation*. 2000;102:1400-1406
12. Koelling TM, Aaronson KD, Cody RJ, Bach DS, Armstrong WF. Prognostic significance of mitral regurgitation and tricuspid regurgitation in patients with left ventricular systolic dysfunction. *American heart journal*. 2002;144:524-529
13. Lapu-Bula R, Robert A, Van Craeynest D, D'Hondt AM, Gerber BL, Pasquet A, Melin JA, De Kock M, Vanoverschelde JL. Contribution of exercise-induced mitral regurgitation to exercise stroke volume and exercise capacity in patients with left ventricular systolic dysfunction. *Circulation*. 2002;106:1342-1348
14. Pierard LA, Lancellotti P. The role of ischemic mitral regurgitation in the pathogenesis of acute pulmonary edema. *The New England journal of medicine*. 2004;351:1627-1634
15. Bertrand PB, Schwammenthal E, Levine RA, Vandervoort PM. Exercise dynamics in secondary mitral regurgitation: Pathophysiology and therapeutic implications. *Circulation*. 2017;135:297-314
16. Stout KK, Verrier ED. Acute valvular regurgitation. *Circulation*. 2009;119:3232-3241

17. Leung DY, Griffin BP, Stewart WJ, Cosgrove DM, 3rd, Thomas JD, Marwick TH. Left ventricular function after valve repair for chronic mitral regurgitation: Predictive value of preoperative assessment of contractile reserve by exercise echocardiography. *Journal of the American College of Cardiology*. 1996;28:1198-1205
18. Nishimura RA, Otto CM, Bonow RO, Carabello BA, Erwin JP, 3rd, Guyton RA, O'Gara PT, Ruiz CE, Skubas NJ, Sorajja P, Sundt TM, 3rd, Thomas JD. 2014 aha/acc guideline for the management of patients with valvular heart disease: Executive summary: A report of the american college of cardiology/american heart association task force on practice guidelines. *Journal of the American College of Cardiology*. 2014;63:2438-2488
19. Hickey MS, Smith LR, Muhlbaier LH, Harrell FE, Jr., Reves JG, Hinohara T, Califf RM, Pryor DB, Rankin JS. Current prognosis of ischemic mitral regurgitation. Implications for future management. *Circulation*. 1988;78:151-59
20. Goldstein D, Moskowitz AJ, Gelijns AC, Ailawadi G, Parides MK, Perrault LP, Hung JW, Voisine P, Dagenais F, Gillinov AM, Thourani V, Argenziano M, Gammie JS, Mack M, Demers P, Atluri P, Rose EA, O'Sullivan K, Williams DL, Bagiella E, Michler RE, Weisel RD, Miller MA, Geller NL, Taddei-Peters WC, Smith PK, Moquete E, Overbey JR, Kron IL, O'Gara PT, Acker MA. Two-year outcomes of surgical treatment of severe ischemic mitral regurgitation. *The New England journal of medicine*. 2016;374:344-353
21. Mihos CG, Yucel E, Santana O. The role of papillary muscle approximation in mitral valve repair for the treatment of secondary mitral regurgitation. *European journal of cardio-thoracic surgery : official journal of the European Association for Cardio-thoracic Surgery*. 2016
22. Acker MA, Parides MK, Perrault LP, Moskowitz AJ, Gelijns AC, Voisine P, Smith PK, Hung JW, Blackstone EH, Puskas JD, Argenziano M, Gammie JS, Mack M, Ascheim DD, Bagiella E, Moquete EG, Ferguson TB, Horvath KA, Geller NL, Miller MA, Woo YJ, D'Alessandro DA, Ailawadi G, Dagenais F, Gardner TJ, O'Gara PT, Michler RE, Kron IL. Mitral-valve repair versus replacement for severe ischemic mitral regurgitation. *The New England journal of medicine*. 2014;370:23-32
23. lung B, Baron G, Tornos P, Gohlke-Barwolf C, Butchart EG, Vahanian A. Valvular heart disease in the community: A european experience. *Current problems in cardiology*. 2007;32:609-661
24. Rankin JS, Hammill BG, Ferguson TB, Jr., Glower DD, O'Brien SM, DeLong ER, Peterson ED, Edwards FH. Determinants of operative mortality in valvular heart surgery. *The Journal of thoracic and cardiovascular surgery*. 2006;131:547-557
25. Di Salvo TG, Acker MA, Dec GW, Byrne JG. Mitral valve surgery in advanced heart failure. *Journal of the American College of Cardiology*. 2010;55:271-282
26. Maisano F, Torracca L, Oppizzi M, Stefano PL, D'Addario G, La Canna G, Zogno M, Alfieri O. The edge-to-edge technique: A simplified method to correct mitral insufficiency. *European journal of cardio-thoracic surgery : official journal of the European Association for Cardio-thoracic Surgery*. 1998;13:240-245; discussion 245-246
27. Feldman T, Kar S, Elmariah S, Smart SC, Trento A, Siegel RJ, Apruzzese P, Fail P, Rinaldi MJ, Smalling RW, Hermlinger JB, Heimansohn D, Gray WA, Grayburn PA, Mack MJ, Lim DS, Ailawadi G, Herrmann HC, Acker MA, Silvestry FE, Foster E, Wang A, Glower DD, Mauri L. Randomized comparison of percutaneous repair and surgery for mitral regurgitation: 5-year results of everest ii. *Journal of the American College of Cardiology*. 2015;66:2844-2854
28. Al-Lawati A, Cheung A. Transcatheter mitral valve replacement. *Interventional cardiology clinics*. 2016;5:109-115